

Key points

Children with urological conditions may suffer from renal insufficiency and associated co-morbidities (e.g. electrolyte imbalance, anaemia, hypertension, and metabolic problems).

The use of irrigation fluid can make it more difficult to estimate blood loss and increases the risk of perioperative hypothermia.

Antibacterial prophylaxis is frequently required for patients with obstructive problems and urinary infections.

Many urological procedures are performed in the lithotomy position that can lead to nerve injuries if careful attention is not paid to patient positioning.

Children with congenital urological abnormalities are at increased risk of developing latex allergy.

Paediatric urological surgery encompasses a wide spectrum of procedures ranging from simple day-case operations such as circumcision to complex cases such as correction of bladder exstrophy undertaken in specialist centres. The anaesthetic techniques used vary according to age, requirements of the surgeon, and medical status of the patient.

The majority of urological problems in children are congenital and therefore distinct from those in adults. This article describes the anaesthetic management of the more commonly performed paediatric urological procedures and also includes a discussion of some of the more complex conditions.

Preoperative evaluation

Preoperative evaluation and preparation are similar to other types of surgery performed in this age group. It is important to appreciate that a favourable outcome depends on the preparation of the whole family unit. Children undergoing genitourinary surgery may face emotional difficulties. There may be increased anxiety due to multiple procedures required for some of the surgical conditions. Older children may have emotional or behavioural problems due to the embarrassing nature of the urological condition particularly if associated with urinary incontinence. For these reasons, many of these patients may benefit from sedative premedication.

Most children for urological surgery are otherwise healthy with isolated urinary problems. Any associated congenital defects would require further investigations (Table 1). Pre-anaesthetic assessment for major surgery must ensure that the haematology and biochemistry results are within normal limits. Any associated cardiac abnormality should be evaluated using echocardiography. In conditions with a high incidence of associated spinal abnormalities, for example, cloacal exstrophy, imaging should be undertaken before considering central neuraxial block for analgesia.

Anaesthetic management

Circumcision and preputioplasty

Circumcision is one of the most common paediatric urological procedures. The incidence of phimosis is 8% in 6–7-yr-olds and 1% in males aged 16–18 yr.¹ The foreskin retracts naturally with increasing age; therefore, physiological phimosis is not an indication for surgery.

The indications for circumcision are recurrent balanitis and balanitis xerotica obliterans (BXO) where the foreskin is fibrosed and adherent to the underlying prepuce. In the condition BXO, the foreskin is removed completely during circumcision. If the foreskin is otherwise healthy, a preputioplasty (dorsal slit with transverse closure) overcomes phimosis while preserving the foreskin.

Religious circumcision is commonly performed in the neonatal period and occasionally in older children. There has historically been controversy surrounding the requirements for pain relief when this is performed earlier than 6–8 weeks of age. Analgesia should always be provided to alleviate the substantial pain associated with the procedure. A ring block or a dorsal nerve block can be used safely in young infants by appropriately experienced clinicians.

The majority of children undergoing circumcision are physically well and it is usually performed as a day-case procedure. An i.v. or inhalation agent may be used for induction of anaesthesia. Airway management using a laryngeal mask airway (LMA) is usually appropriate, although small infants may require tracheal intubation.

Analgesia is provided using either a penile block or a single caudal injection and supplemented with simple systemic analgesia with acetaminophen and non-steroidal anti-inflammatory drugs (NSAIDs) (if not contraindicated). The use of a subcutaneous ring block at the base of the penis has been associated with a higher failure and complication rate than caudal or penile nerve block.² Caudal additives

Monica Gandhi MBBS MD FRCA

Clinical Fellow in Paediatric Anaesthesia
Royal Manchester Children's Hospital
Oxford Road
Manchester M13 9WL
UK

Rita Vashisht DA FFARCSI FRCA

Consultant Paediatric Anaesthetist
Royal Manchester Children's Hospital
Oxford Road
Manchester M13 9WL
UK
Tel/fax: +44 1617011263
E-mail: rita.vashisht@cmft.nhs.uk
(for correspondence)

Table 1 Congenital syndromes associated with urological anomalies

VACTER association	Vertebral segmentation, imperforate anus, cardiac defects, tracheo-oesophageal fistula, absent radius, renal abnormalities
CHARGE syndrome	Coloboma of iris/retina, heart defects, choanal atresia, retarded growth, genital hypoplasia, genital and urinary abnormalities, ear abnormalities, and hearing defects
DiGeorge syndrome	Cardiac defects, abnormal facies, thymic aplasia/hypoplasia and immunodeficiency, cleft lip/palate, colobomas, hypocalcemia, renal anomalies
Brachio-oto-renal syndrome	Brachial cysts/fistulas, malformations of the ear, preauricular pits, hearing loss, renal anomalies
Townes-Brocks syndrome	Ear defects and hearing loss, malformation of the hand, imperforate anus/rectourinary fistula, renal anomalies

such as preservative-free ketamine or clonidine, although unlicensed, help to prolong the duration of the block but may delay mobilization.³ Therefore, for the older child, a penile block may be preferable in day-case surgery.

Hypospadias

Hypospadias is a relatively common congenital defect with an incidence of 1:350 male births.¹ The urinary meatus is on the undersurface of the penis (ventral) and there may be an associated downward curvature of the penis, called chordee. Surgical correction is performed at 6–18 months of age (Fig. 1A and B).

Epispadias is a relatively rare condition and presents with the urinary meatus on the dorsum of the penis. It is rarely isolated and presents as a spectrum of conditions associated with failure of fusion of the anterior abdominal wall and pelvis, as the exstrophy–epispadias complex.

In most cases of hypospadias, the urethral meatus is in the mid or distal penis and the operation is straightforward. In severe hypospadias, the meatus is situated at the base of the penis or in the perineum and the operation is more complex and may require a staged repair. In revision surgery, if there is inadequate local tissue for the reconstruction, a graft of buccal mucosa may be required. Severe hypospadias with unilateral or bilateral impalpable testes or ambiguous genitalia requires genetic and endocrine investigations

to exclude congenital adrenal hyperplasia. Other congenital anomalies are uncommon and renal function is usually normal.

General anaesthesia (GA) is frequently combined with a regional anaesthetic technique for hypospadias correction. Orotracheal intubation is preferred for younger children undergoing prolonged procedures and is also useful when a buccal graft is required. An LMA with spontaneous ventilation may be used in older children. Minor hypospadias may be performed as a day-case procedure, children often being discharged with an indwelling urinary catheter. In these cases, consideration must be given to the mode of analgesia used, particularly in older children, to prevent delay in mobilization.

For hypospadias repair, caudal extradural block is effective and reduces the requirement for postoperative supplementary opioid administration.² Additives such as clonidine or preservative-free ketamine are useful to extend the duration of block in these cases. Penile nerve block may be suitable only if the hypospadias is distal and is associated with a lower incidence of urinary retention compared with a caudal block.⁴ In one study, penile blocks performed at the beginning and conclusion of hypospadias repair, respectively, provided better postoperative pain control than a single block performed before surgery.²

Orchidopexy

Cryptorchidism (absence of one or both testes from the scrotum) usually represents failure of the testis to descend during fetal development from the abdomen into the ipsilateral scrotum. It affects 1% of full-term infants at 1 yr and 5% of those born prematurely.¹ Orchidopexy involves surgical exploration of the inguinal region with dissection and traction on the spermatic cord. A scrotal incision is also required to fix the testis in its normal position. Indications for surgery are to preserve fertility, reduce the incidence of testicular trauma/torsion, and to aid the detection of a testicular malignancy. There is four- to seven-fold increase risk of undescended testes being associated with testicular malignancy.

Knowledge of the presence and location of the testis directly influences clinical management. Where the testis is non-palpable, laparoscopy helps to examine the abdomen and locate the testis.

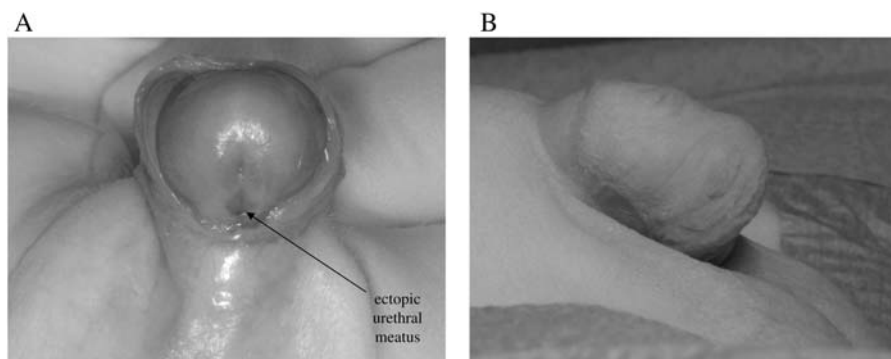


Fig 1 (A) Glandular hypospadias with ventral displacement of the urethral meatus. (B) Abnormal downward curvature of the penis (chordee) in the same patient. Figures reproduced with the permission of the child's parents.

Before starting diagnostic laparoscopy, it is recommended that the child should be examined again under GA because a previously non-palpable testis might now be palpable in the groin.

Removal or orchidolysis and orchidopexy can be performed via laparoscopic access. If the testis is very high or located intra-abdominally, a two-stage procedure may be used. During the first stage, the testicular vessels on the affected side are divided to increase mobility of the testis. The testis now depends precariously for its blood supply on the vessels to the vas deferens. Therefore, the second stage is delayed for 6 months before a combined inguinal and laparoscopic approach brings the testis down to the scrotum.

I.V. or inhalation induction is performed depending on the age of the child and preference of the anaesthetist. If surgery is performed via the inguinal approach, spontaneous respiration using an LMA is commonly preferred in the older child. Anaesthesia is maintained with volatile agents in oxygen and air or nitrous oxide. In cases of laparoscopic-assisted procedures, the airway is secured using a tracheal tube.⁵

Analgesia for unilateral procedures may be provided by ilioinguinal block and local anaesthetic infiltration of scrotal wound by the surgeon. With bilateral procedures, a caudal extradural block using 1 ml kg⁻¹ of 0.25% bupivacaine (maximum 20 ml) to achieve a block up to the level T10 is required. The use of a caudal block requires less supplementary analgesia when compared with ilioinguinal nerve block plus local infiltration. There is no demonstrable difference in complications such as time to micturition, motor block, and nausea or vomiting, between the two techniques.²

Orchidopexy is usually performed as a day-case procedure. It is associated with an increased risk of postoperative nausea and vomiting due to manipulation of the testis. Prophylactic anti-emetics should be used.

Testicular torsion

The acute scrotum is a urological emergency. The differential diagnosis of children presenting with acute scrotal pain include torsion of the testis, torsion of the appendix testis, or epididymitis/epididymo-orchitis. Torsion of the testis occurs most often in the neonatal period and around puberty, while torsion of the appendix testes occurs over a wider age range. Acute epididymitis affects two age groups, either below the age of 1 yr or between 12 and 15 yr.

Urgent surgical exploration is mandatory in all cases of scrotal pain to exclude torsion. In testicular torsion, there is complete interruption in the blood supply and complete necrosis of the testis can occur in 6 h. If the presentation is delayed for 1–2 days, it is very likely that the ischaemic damage is permanent. With epididymo-orchitis, children are frequently febrile and dehydrated, but the presence of a fever does not allow the diagnosis of an infective cause to be confidently made. Fluid resuscitation may be required before operation and continued during the surgery. Even if the child is fasted, pain and distress may delay gastric emptying, thus a rapid sequence induction is indicated in most cases. An

LMA is only considered if the anaesthetist is confident that there is no risk of aspiration.

A combination of acetaminophen, NSAID, local anaesthetic infiltration, and an i.v. opioid (fentanyl 1–2 µg kg⁻¹, morphine 100–150 µg kg⁻¹) is useful. A caudal extradural block is widely used for this procedure.

Manipulation of the testis may cause a vagal response and atropine or glycopyrrolate should be available. Testicular surgery is associated with a high incidence of postoperative nausea vomiting, and therefore, prophylactic anti-emetics should be administered particularly to the child >3 yr old.

Cystoscopy and percutaneous nephrolithotomy

Cystoscopy is the most common diagnostic procedure performed in children under GA. It is a short procedure and is commonly performed using an LMA and spontaneous ventilation outside infancy. A deep plane of anaesthesia and adequate analgesia is important before insertion of the cystoscope as urethral stimulation may precipitate laryngospasm. Although this is a short procedure, it is particularly important to warm irrigating solutions to avoid hypothermia in smaller children. Particular attention should be paid to careful positioning of the child in the lithotomy position to decrease the risk of nerve damage and injury to the hips. Application of a local anaesthetic gel to the urethra is useful for pain relief after cystoscopy.

Urolithiasis may be recurrent and every effort should be made to discover if there is an underlying metabolic abnormality, for example, hypercalcemia, so that it can be treated appropriately. Currently, most renal stones can be managed by extra-corporeal shock wave lithotripsy (ESWL). Endoscopic treatment can be used for ureteric and bladder stones. Percutaneous removal of stones, percutaneous nephrolithotomy (PCNL), is possible for renal stones in children. A small proportion of children with large and complex stones will require an open surgical approach.

Surgical technique for ESWL in children is similar to that in adults, but in children, it is usually performed under GA and rarely under sedation. Postoperative vomiting may be a problem due to high-pressure irrigation of the kidney during ureteroscopy and PCNL; therefore, prophylactic anti-emetics may be useful.

Laparoscopic urinary tract procedures

Laparoscopic surgery is well established in paediatric urology for diagnostic and therapeutic indications. Advantages over open procedures include reduced postoperative pain, decreased wound complications, quicker recovery, and improved cosmetic results.⁶ Diagnostic laparoscopy is commonly performed for impalpable testis, tumour staging, and biopsy. Therapeutic laparoscopy is increasingly popular for a variety of procedures, including orchidopexy, nephrectomy, heminephrectomy, and pyeloplasty.

Tracheal intubation with controlled ventilation is used for paediatric laparoscopy. When a transperitoneal approach is used for surgery, insufflation raises intra-abdominal pressure. A cuffed

tracheal tube may be beneficial in some cases.⁵ Laparoscopic procedures produce intense surgical stimulation until almost the end of surgery. The analgesic technique used should take this into consideration. Remifentanyl is ideally suited for these procedures.⁷ The recommended dose range is 0.1–0.5 $\mu\text{g kg}^{-1} \text{min}^{-1}$.² It is important to provide adequate analgesia and good relaxation similar to that provided for major laparotomy. Local anaesthetic infiltration of port sites, local anaesthetic instillation into the retroperitoneal space, and intercostal blocks, as part of a multimodal analgesic strategy helps reduce postoperative pain after laparoscopy.²

Pyeloplasty and nephrectomy

Pyeloplasty is performed to relieve pelviureteric junction obstruction that produces partial blockage of the ureter. This causes hydronephrosis and the prolonged back-pressure may result in diminished renal function and subsequent loss of renal cortex.

Classical pyeloplasty is an open procedure using a subcostal incision. Transabdominal or posterior approaches are also possible. Nephrectomy or heminephrectomy is performed for various underlying pathologies that include a multicystic dysplastic kidney, congenital renal dysplasia, severe reflux nephropathy, and severe obstructive uropathy. Both these procedures are now increasingly performed laparoscopically.

Most of these children are healthy with normal renal function and have no electrolyte disturbances. The children may be placed in a lateral or prone position. GA is usually maintained with tracheal intubation and controlled ventilation. When performed laparoscopically, the incision does not split muscles and is consequently less painful. Local anaesthetic infiltration combined with simple analgesics and oral opioids are usually adequate.

Open procedures are suitable for combined GA and regional techniques. An epidural catheter, ultrasound-guided unilateral transversus abdominis plane block, or an opioid infusion are all considered to be adequate for analgesia.²

Some children have underlying conditions such as spina bifida, renal artery stenosis, polycystic disease, or chronic renal failure that significantly affects the anaesthetic technique used. Important systemic considerations are anaemia, hyperkalaemia, fluid overload, and hypertension.

Wilm's tumour (nephroblastoma) is the most common childhood malignancy involving the kidney and usually presents in the pre-school child with a peak incidence around 3 yr of age. Surgical intervention is required depending on the stage of the tumour. Bleeding is a major consideration in the removal of a Wilm's tumour, especially when it has extended into the inferior vena cava. Therefore, cross-matched blood should always be available. Analgesia should take into account the extensive nature of the procedure and an epidural or an opioid infusion may be used.

Prune belly syndrome

Prune belly syndrome is also known as Eagle–Barrett syndrome. It occurs in 1:40 000 births and is predominant in boys (95%).

A genetic predisposition has been suggested. The mass of wrinkled skin that is often present on the abdomen gives the syndrome its name.

Bilateral cryptorchidism and dilatation of the ureters and bladder are constant features. Urethral obstruction leads to bladder distension, hydroureter, and hydronephrosis with small dysplastic kidneys. The patients are prone to recurrent urinary tract infections. Abdominal distension leads to abdominal muscle deficiency and excessive abdominal skin. Lower limb deficiency occurs due to iliac vessel compression secondary to bladder distension. Surgical treatment is required to relieve obstruction of the urinary tract when reflux gives rise to repeated infections and orchidopexy. Abdominal wall reconstruction is undertaken to improve respiratory function and cosmesis.

Deficiency of the abdominal wall and inability to cough causes retention of secretions and respiratory tract infections. Preoperative respiratory infections should be adequately treated. Intraoperatively controlled ventilation is necessary to avoid hypoventilation. Neuromuscular blocking agents should be used at the time of reconstruction of the abdominal wall. These children are at high risk of vomiting and aspiration and this may occur after operation following extubation. After operation, respiratory infections are common. Continued postoperative mechanical ventilation may be required for children undergoing extensive abdominal procedures and when significant pulmonary disease is present.

Bladder exstrophy

Bladder exstrophy is a rare congenital malformation affecting the genitourinary tract. It is one component of a spectrum of manifestations ranging from cloacal exstrophy, involving the bladder and intestines, to isolated epispadias (exstrophy–epispadias complex). Classical bladder exstrophy is the most common and affects 1 in 200 000 live births. There is a defect of lower abdominal wall and the anterior wall of the urinary bladder. The posterior wall of the urinary bladder appears everted (exstrophy) with varying degree of pelvic diastasis.

Goals of reconstructive surgery are to achieve closure of the bladder, obtain urinary continence while preserving renal function, and producing satisfactory appearance and function of the external genitalia. Surgical correction could either be a single-staged closure of the bladder and epispadias or a planned, staged repair. Multiple procedures are usually necessary in the first year of life and they are prone to develop latex allergy. Pelvic osteotomies have been shown to reduce the risk of wound dehiscence and bladder prolapse.

Primary surgical repair requires several hours of surgery with fluid and blood loss that can be considerable in the newborn. It is recommended that adequate venous access and invasive vascular monitoring be utilized. Postoperative intensive care will be required.

Latex allergy in paediatric urological patients

Latex, a natural rubber, is the sap of the tree, *Hevea brasiliensis*, and is used in the manufacture of rubber gloves and other medical

products. Sensitization may occur due to early and prolonged exposure to products containing latex. Children undergoing repeated surgery, particularly in the first year of life, are at greater risk of developing latex allergy, for example, spina bifida, multiple urinary tract procedures as in bladder exstrophy repair.

In the perioperative period, a type 1 hypersensitivity reaction may be first recognized by bronchospasm and cardiovascular collapse. This can be delayed and occur 30–60 min after induction or even in the postoperative period. Delayed type IV hypersensitivity may occur 6–48 h after exposure and manifest as watery and itchy eyes, sneezing, and coughing. There may be associated allergy to certain types of foodstuffs, for example, banana, chestnut, avocado, and kiwi fruit. Avoidance of latex products in these patients will prevent severe anaphylactic reactions.

Postoperative analgesia

- Minor and intermediate urological procedures: local anaesthetic wound infiltration, simple analgesics, ilioinguinal nerve block, or caudal analgesia.²
- Major urological procedures: multimodal analgesia using NSAIDs (unless contraindicated) and acetaminophen, i.v. opioids, or epidural analgesia. I.V. opioids either as a continuous infusion or nurse- or patient-controlled can be effective. Epidural analgesia using local anaesthetic and additives such as opioid or clonidine may improve analgesia, but side-effects such as nausea, vomiting, itching, and sedation are also increased.²
- Laparoscopic surgery: infiltration of port sites with local anaesthetic as part of a multimodal analgesic technique is adequate.²
- Sensory innervations important to consider for urological procedures (Table 2).

The common regional anaesthetic techniques useful in urological surgery are now briefly described. A good knowledge of the sensory innervation of the genitourinary tract is important to ensure the effective use of regional anaesthesia (Table 2).

Table 2 Sensory innervations of the genitourinary system

Pelvic parasympathetic nerves via pelvic plexus (S2, 3, 4)	Innervate detrusor muscle and inhibit the internal sphincter of the bladder. Afferent fibres from the urinary bladder for pain and distension travel via these fibres
Pelvic sympathetic nerves from the hypogastric plexus (presacral nerves)	Inhibit the detrusor muscle and they are motor to the internal sphincter of the bladder (responsible for painful reflex spasms)
Kidney	T10–L1
Ureter	T11–L1
Testes	T10
Penis	Dorsal nerve of the penis, a terminal branch of the pudendal nerve (S2, 3, 4); dorsal part of root of the penis–ilioinguinal nerve (L1).
Scrotum	Anterior one-third of the scrotal skin is supplied by ilioinguinal (L1), posterior two-third of the skin is supplied by the perineal nerve (S2), and lateral by the posterior cutaneous nerve of the thigh (S3)

Caudal epidural

Caudal block is useful for analgesia after infraumbilical operations (T10). Levobupivacaine is currently the most commonly used local anaesthetic due to its favourable side-effect profile.

One of the major limitations of the single-injection technique is a relatively short duration of postoperative analgesia (4–6 h). The use of opioids, preservative-free ketamine, or clonidine as adjuncts results in clinically relevant prolongation of postoperative analgesia. The recommended doses are morphine 33–50 $\mu\text{g kg}^{-1}$, S(+)-ketamine 0.5–1.0 mg kg^{-1} , or preservative-free racemic ketamine 1 mg kg^{-1} and clonidine 1–2 $\mu\text{g kg}^{-1}$.⁸ Ultrasound imaging and epidural electrical stimulation (Tsui test)⁹ are options to accurately position a caudal catheter.

Ilioinguinal/iliohypogastric nerve block

This nerve block is commonly used for inguinal herniotomy and the groin incision of orchidopexy. Landmark techniques have been used to place the needle close to the nerve to obtain a successful block. Variable distances medial and inferior to the anterior superior iliac spine (ASIS) have been described. Anatomical variations in growing children result in a failure rate of 10–25%, particularly in children aged <2 yr.

A technique suggested to be most successful recommends a distance of 5–10 mm medial and inferior to ASIS in infants (Schulte-Steinberg). Puncture at the junction of lateral one-fourth and the medial three-fourths of a line joining the ASIS and the umbilicus is also recommended (Von Bahr).¹⁰ A short-bevel needle is advanced till a fascial ‘click’ is detected and a dose of 0.5 ml kg^{-1} of levobupivacaine 0.25% is injected for a unilateral block. Performing this block under ultrasound guidance improves the success rate.¹¹

Penile nerve block

This block is often used for circumcision and for minor hypospadias surgery. Point of entry of the needle is just below the symphysis pubis, on either side of the suspensory ligament. This helps to avoid the midline vessels. The needle is directed posteriorly, medially, and slightly caudally on each side until loss of resistance (penetration of Buck’s fascia) is felt. Levobupivacaine, 1 $\text{ml}+0.1 \text{ ml kg}^{-1}$ on each side,¹² ensures a satisfactory nerve block lasting for up to 6 h. Epinephrine containing solutions are contraindicated as severe arterial vasoconstriction can cause ischaemia or necrosis. A double-check procedure should be used to ensure only plain local anaesthetic solutions are used for this block.

Conflict of interest

None declared.

References

1. Tekgül S, Riedmiller H, Gerharz E *et al.* Guidelines on paediatric urology. *Eur Soc Paediatr Urol* 2008; March: 6
2. Good practice in postoperative and procedural pain management. *Paediatr Anaesth* 2008; **18**: 43
3. Margetts L, Carr A, McFadyen G *et al.* A comparison of caudal bupivacaine and ketamine with penile block for paediatric circumcision. *Eur J Anaesthesiol* 2008; **25**: 1009–13
4. Metzelder ML, Kuebler FJ, Glueer S *et al.* Penile block is associated with less urinary retention than caudal anesthesia in distal hypospadias repair in children. *World J Urol* 2009; DOI 10.1007/s00345-009-0420-2.
5. Weber T, Ge Salvi N, Wolf A *et al.* Cuffed vs non-cuffed endotracheal tubes for pediatric anesthesia. *Paediatr Anaesth* 2009; **19**: 46–54
6. Neheman A, Noh PH, Brenn R, Gonzalez R. Laparoscopic urinary tract surgery in infants weighing 6 kg or less: perioperative considerations and comparison. *J Urol* 2008; **179**: 1534–8
7. Croizer TA. *Anaesthesia for Minimally Invasive Surgery*. Cambridge: Cambridge University Press, 2004; 56–7
8. Lohnquist PA. Adjuncts to caudal block in children—Quo Vadis? *Br J Anaesth* 2005; **95**: 431–3
9. Tsui BCH. Innovative approaches to neuraxial blockade in children: the introduction of epidural nerve root stimulation and ultrasound guidance for epidural catheter placement. *Pain Res Manag* 2006; **11**: 173–80
10. Van Schoor AN, Boon JM, Bosenberg AT *et al.* Anatomical considerations of the pediatric ilioinguinal/iliohypogastric nerve block. *Paediatr Anaesth* 2005; **15**: 371–7
11. Willschke H, Marhofer P, Bösenberg A *et al.* Ultrasonography for ilioinguinal/iliohypogastric nerve blocks in children. *Br J Anaesth* 2005; **95**: 226–30
12. Brown TCK. The anatomy and technique of penile block. World Federation of Societies of Anaesthesiologists. *Update in Anaesthesia* 1992: 6

Please see multiple choice questions 16–19.