

MINIMALLY INVASIVE PEDIATRIC SURGERY



Prof.R.K.Mishra



World Laparoscopy Hospital

Advance Laparoscopic Surgery



A large, stylized illustration of two hands shaking in a firm grip, rendered in a teal color. The hands are positioned diagonally across the frame, with the left hand at the bottom left and the right hand at the top right.

There are no great discoveries or advances as long
as there are unhappy children in the world.

Albert Einstein



Special Consideration in Paediatric Patients

- The umbilical vessels are of large diameter.
- Closure of the open processus vaginalis may not have been completed
- The abdominal cavity volume is small
- The internal abdominal wall surface is less
- The abdominal wall thickness is less
- The aortic-iliac axis is very close to the abdominal wall.



Special Consideration

- Urinary catheters are unnecessary, because a full bladder seldom impedes the intra-abdominal view.
- Older children should go to the toilet before laparoscopy.
- Enemas are also not essential, since they will not necessarily empty the colon, and may even distend it.



Anaesthetic considerations

- Capnography, Pulse oximetry, NIBP and ECG.
- Adjust ventilation to end-tidal CO₂, and increase ventilation up to 60% via respiratory rate.
- A positive end-expiratory pressure of 3–5 cm H₂O is recommended to prevent microatelectasis and intrapulmonary shunting.
- When volatile anesthetics like halothane are used, arrhythmia in hypercapnia should be considered.
- Isoflurane or Sevoflurane are less likely to lead to myocardial depression



Access Technique

- The way of Insertion of Veress needle & trocar is same as in adult
- **Insufflation rates**
 - < 1 year: 0.3 liter / minute
 - > 1 year: 0.5 liter / minute
 - > 5 years: 1.0 liter / minute
- **Preset pressure same as adult 12 mm Hg**



Port Position

- According to Base-ball diamond concept
- Size of trocar and canulla is 5 and 2 mm
- For suturing needle should be inserted directly
- Sutures 4.0 and needle sizes of 18–20 mm are adequate for small infants
- Depending on the size of the abdominal cavity, the suture is cut to an approximate length of 8-12 cm.

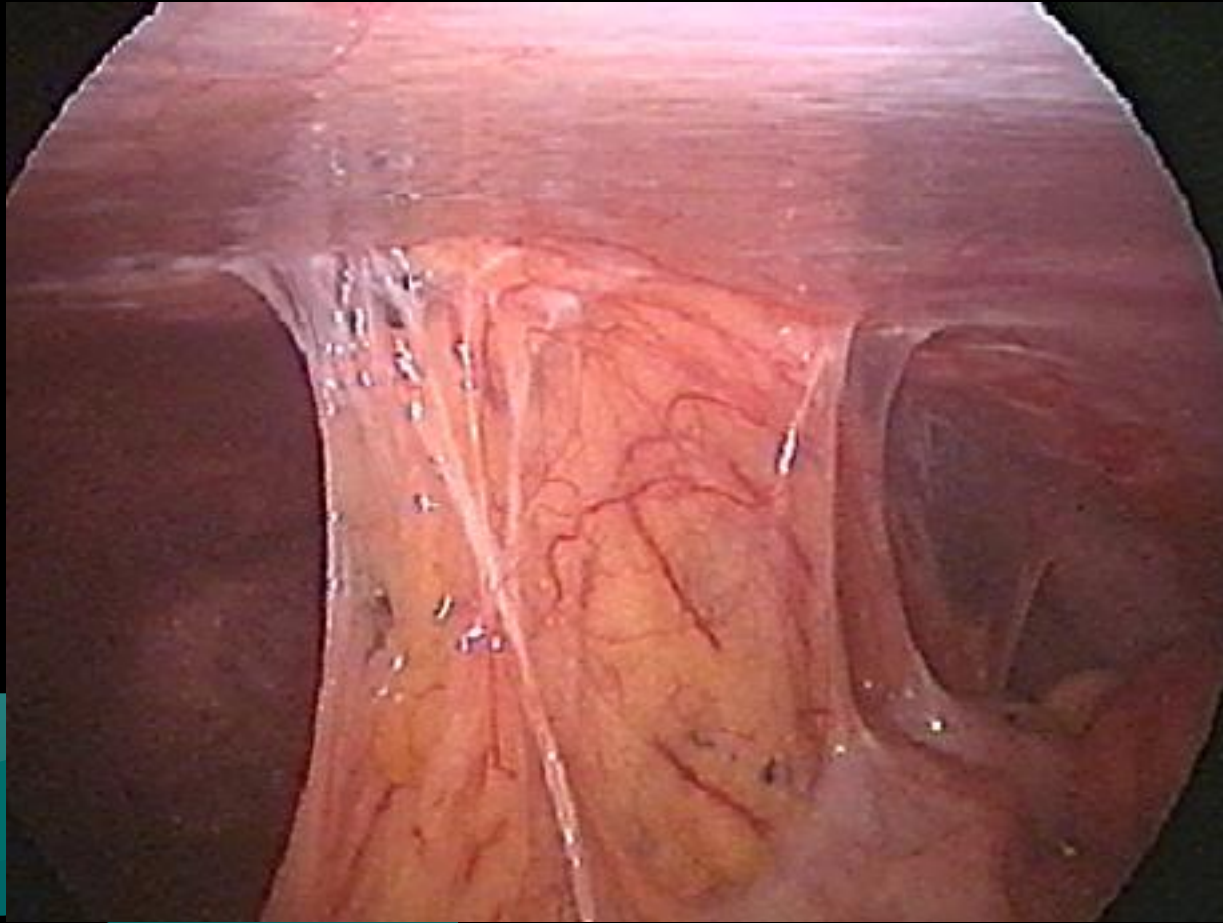


Diagnostic Laparoscopy

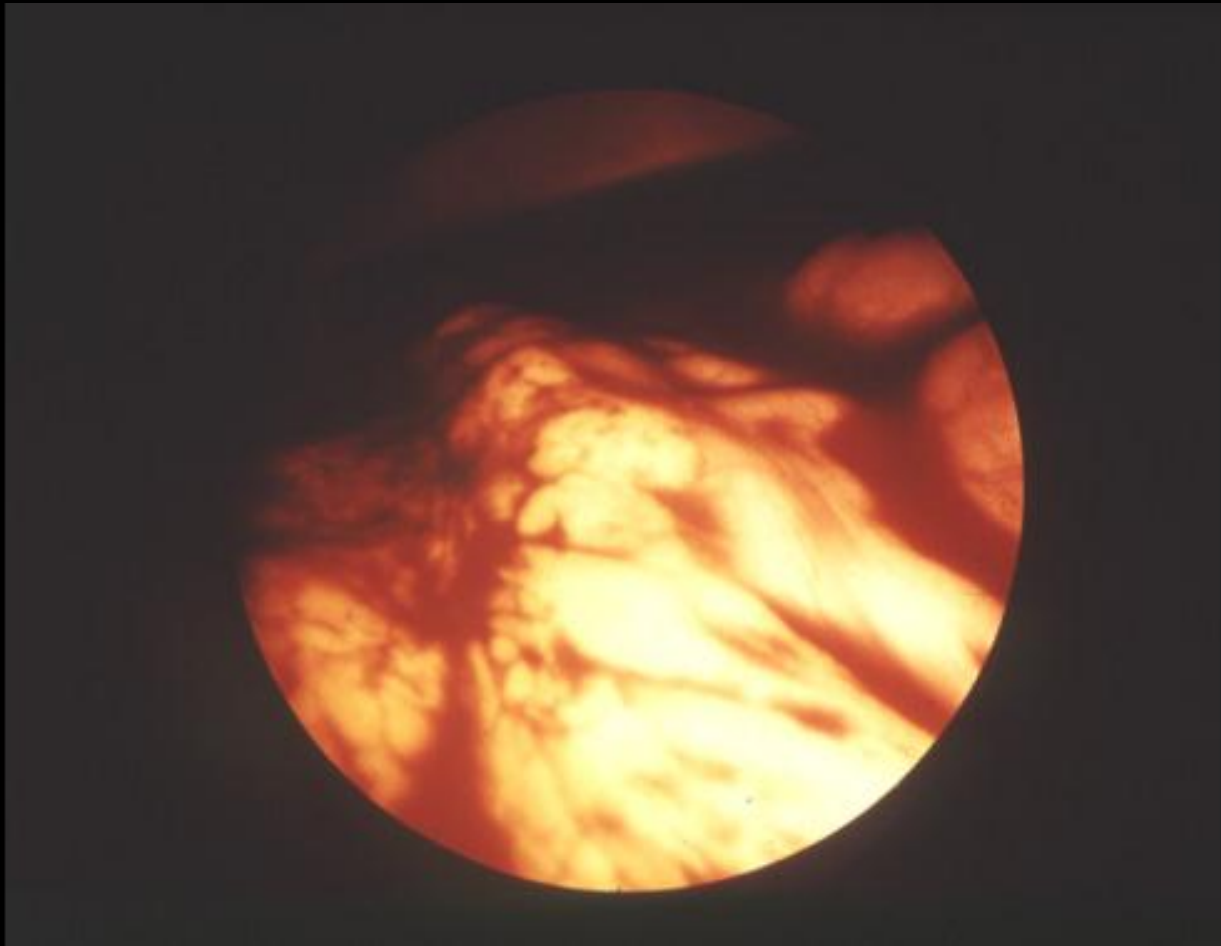
- Findings look slightly different to laparoscopic pictures of adult patients.
- There is less fat and all structures are more readily visible.
- Enlarged mesenteric lymph nodes are frequently seen in children, even in children without related symptoms.



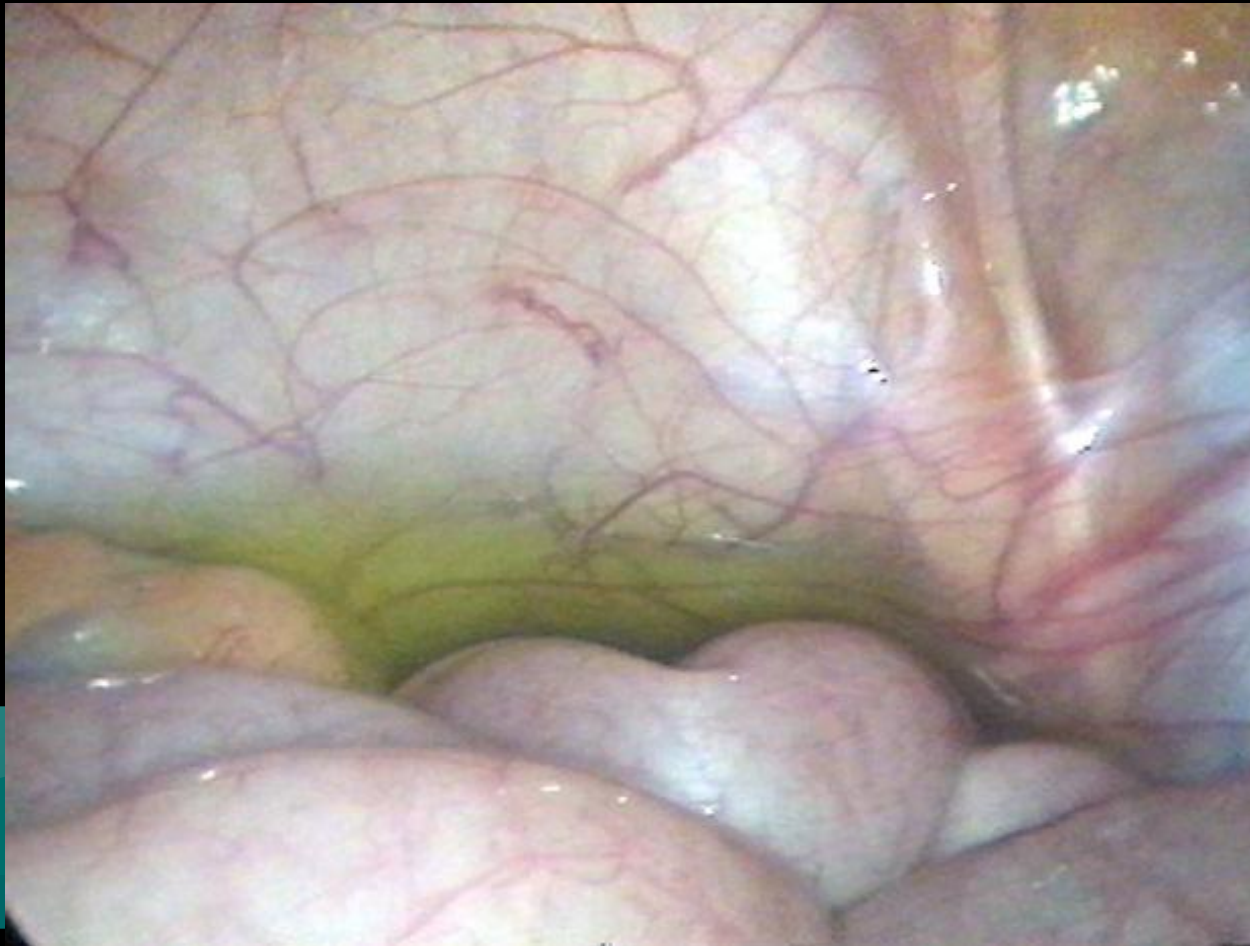Adhesions



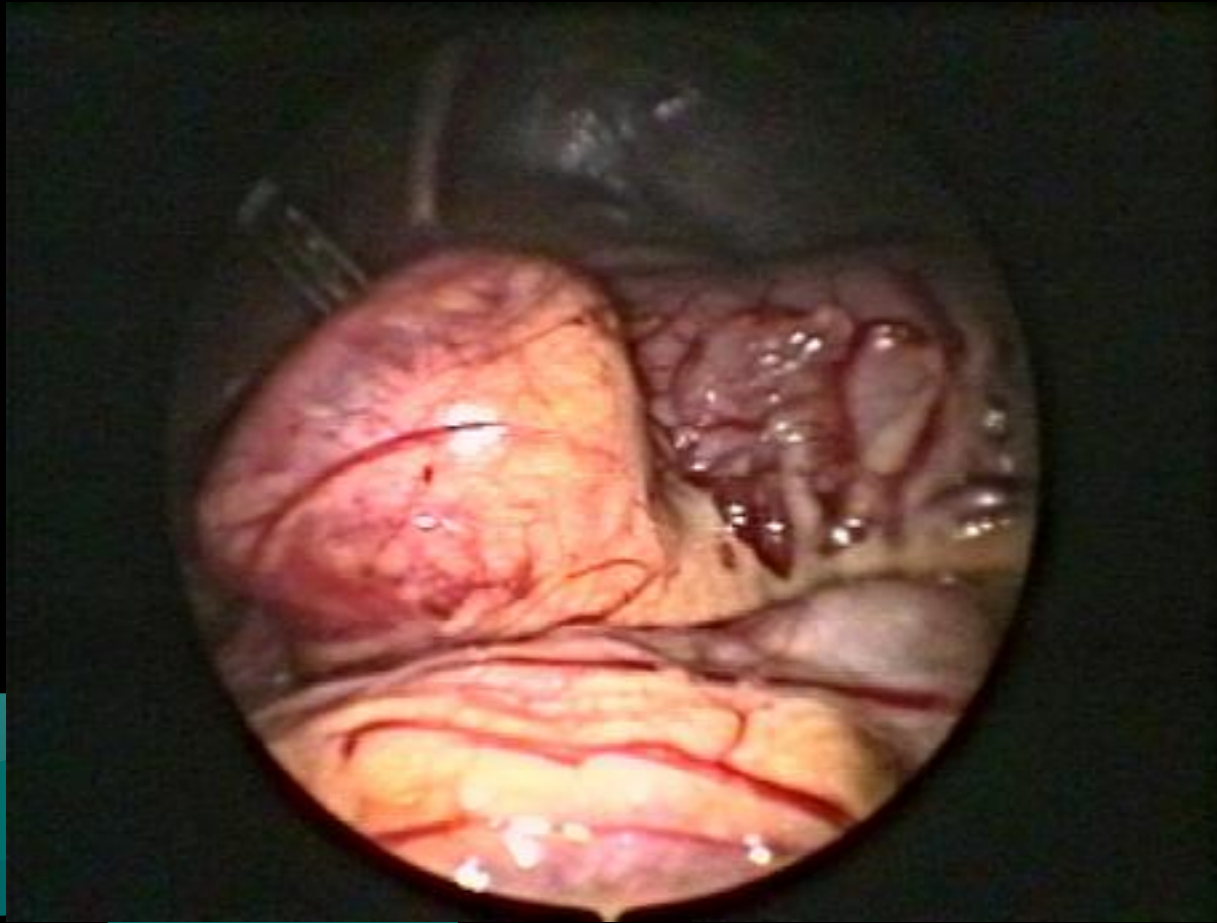
Abdominal Trauma



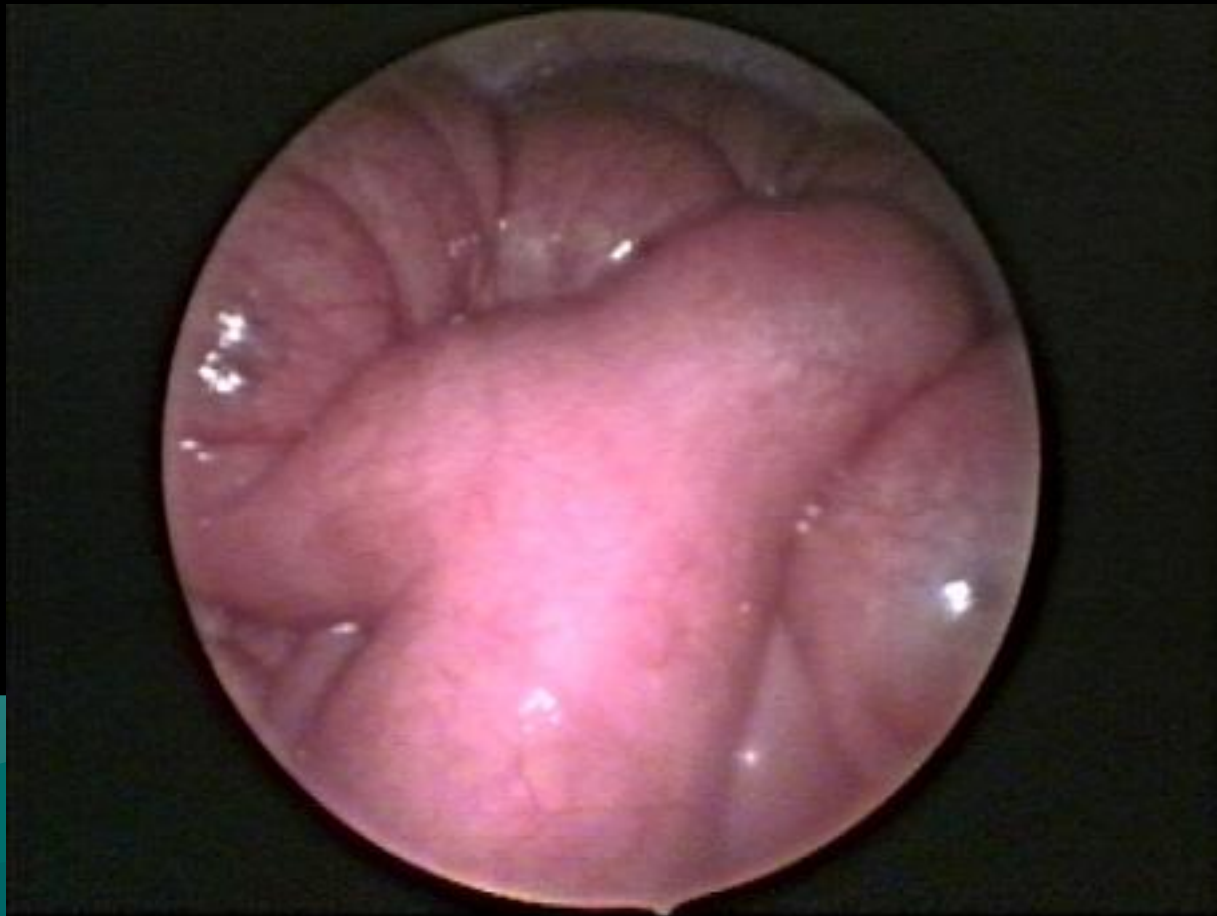
Fluid collection



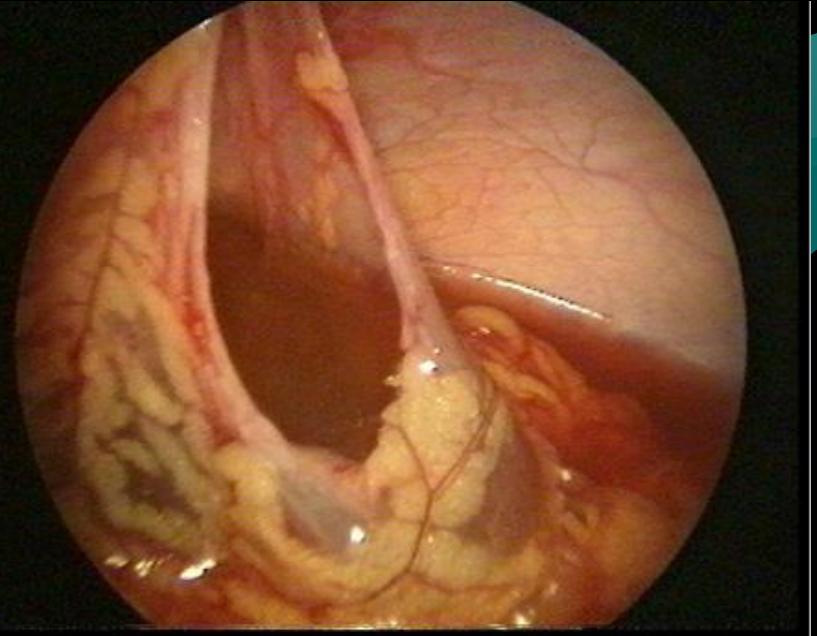
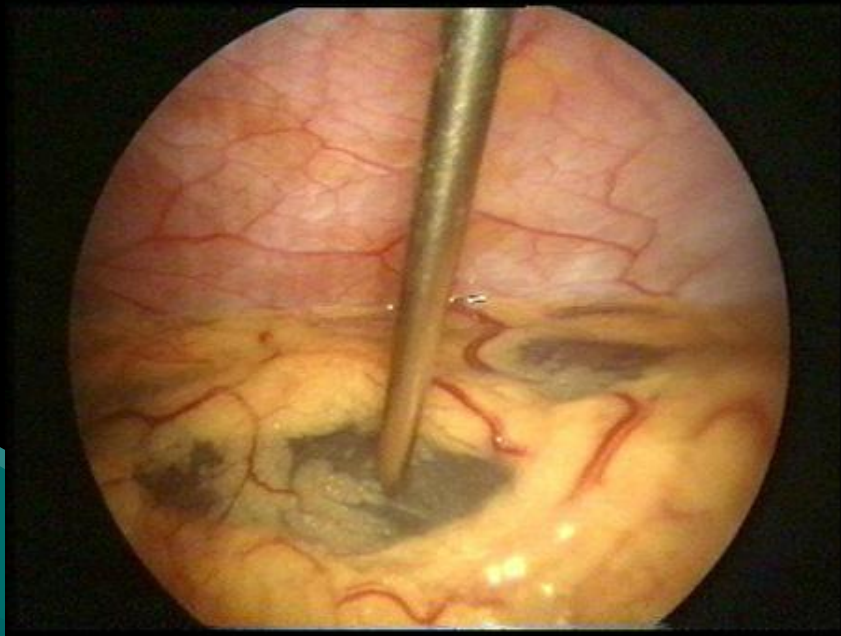
Lymphoma



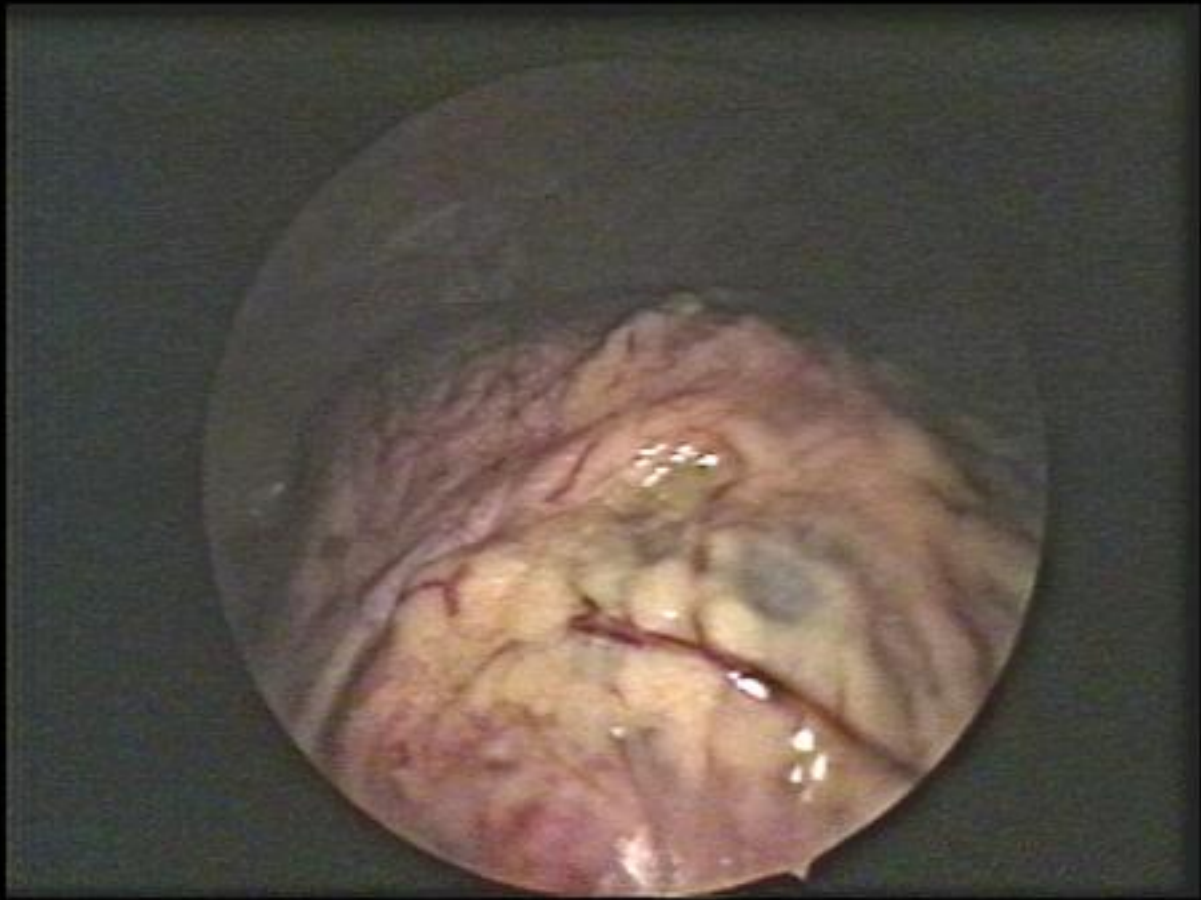
Meckel's diverticulitis



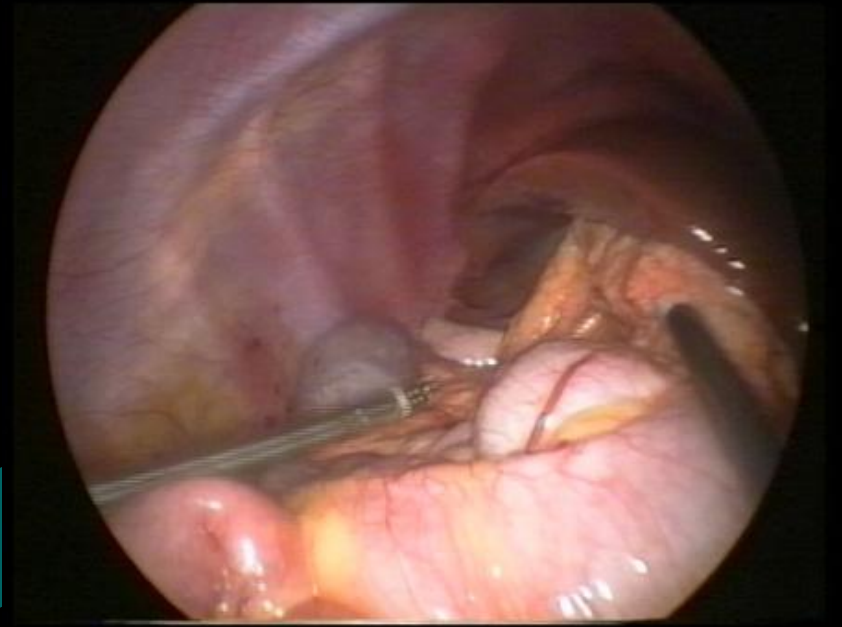
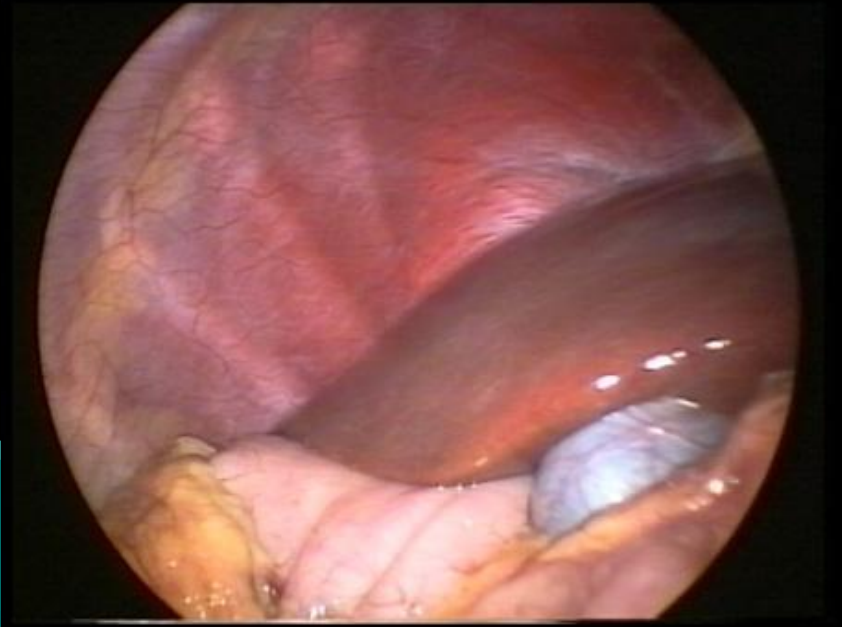
Omentum cysts



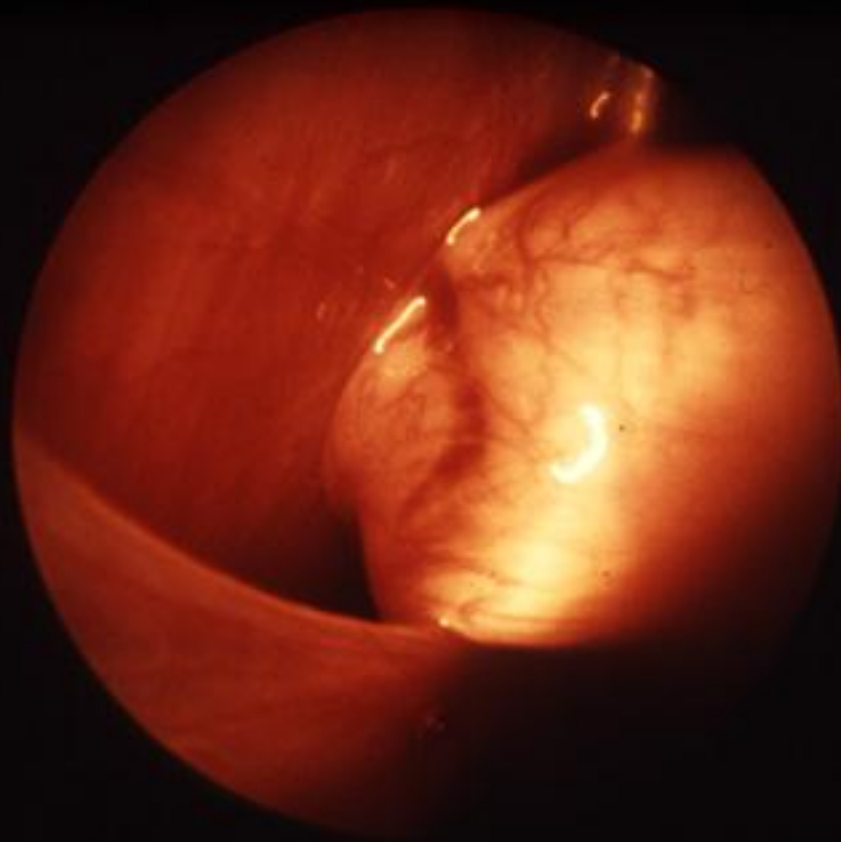
Pancreatic cysts



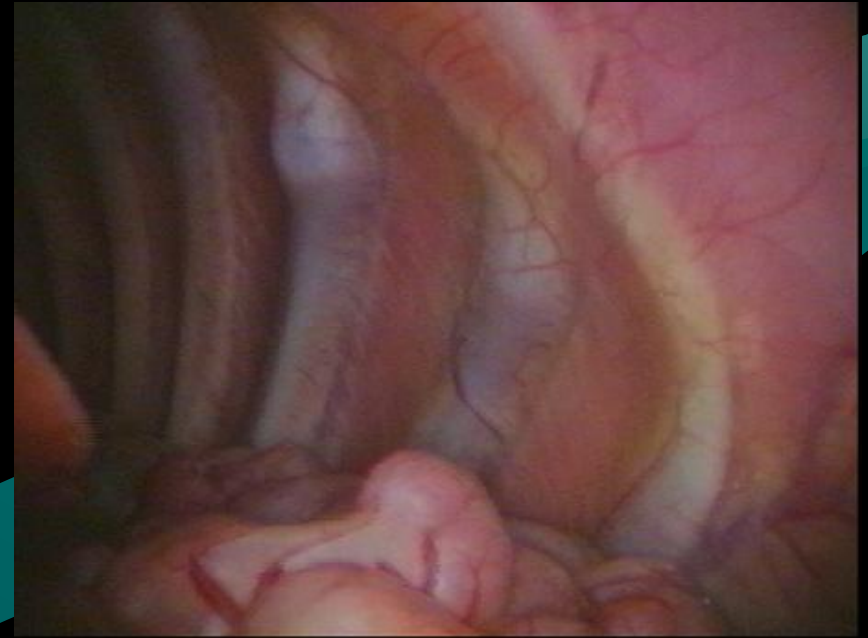
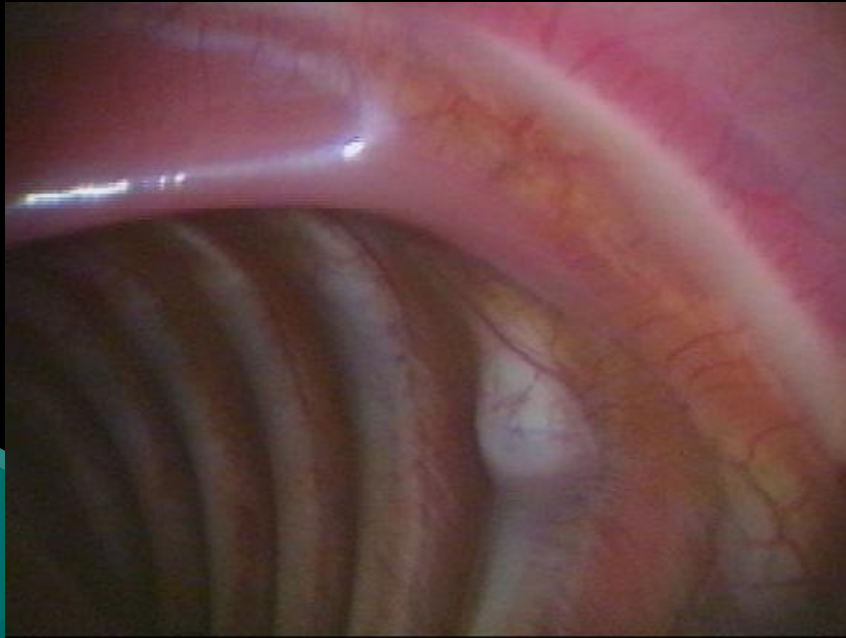
Situs inversus



Diaphragmatic hernia

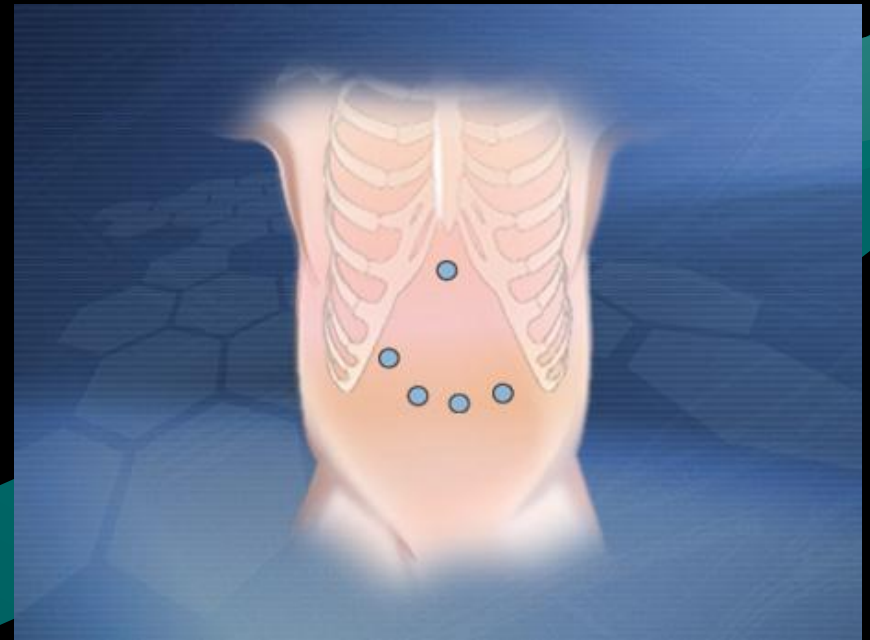

Aggenesis of the diaphragm

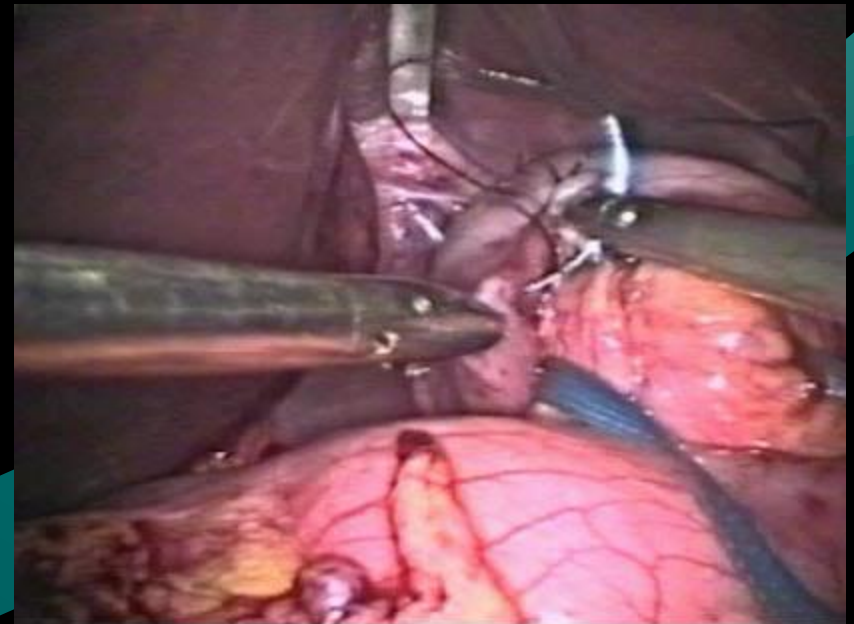
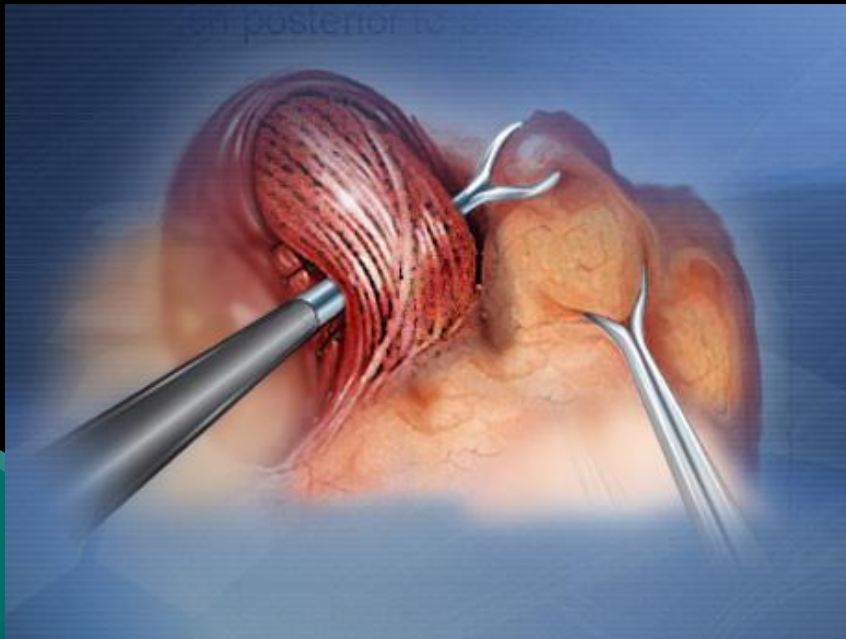


Paediatric Fundoplication

- In Europe, funduplications are infrequent procedures in children.
- A five-port technique is routinely used



Paediatric Fundoplication

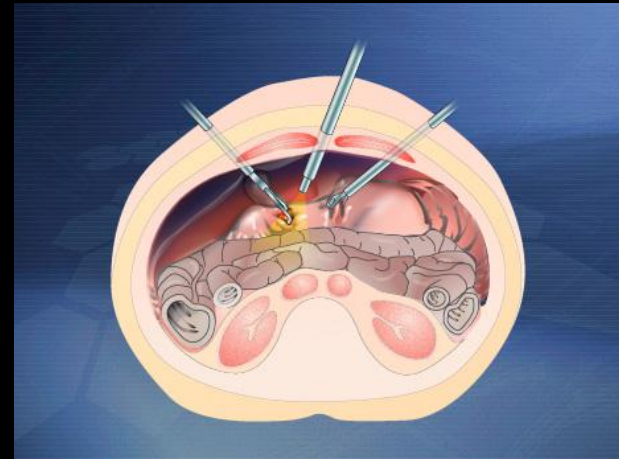


Nissen is better than Toupet in Children

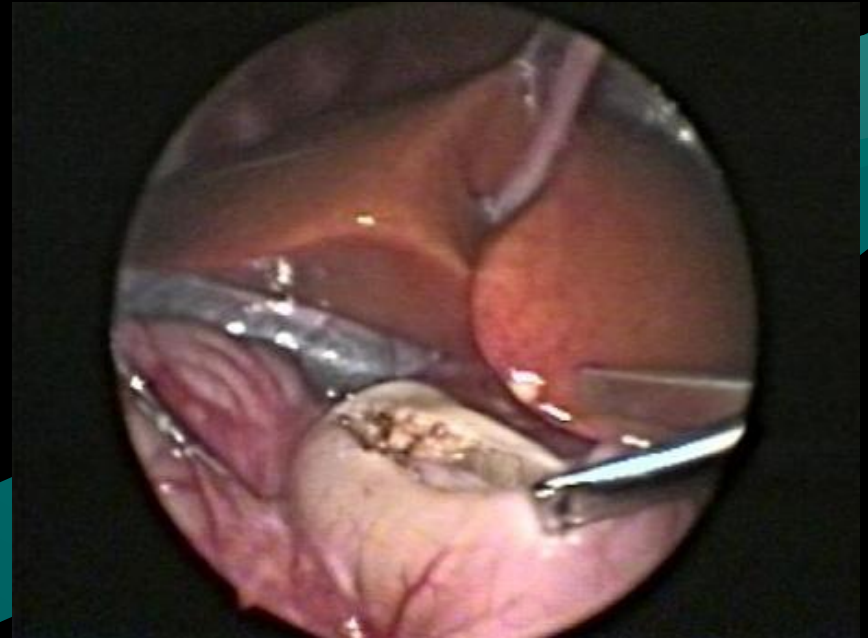
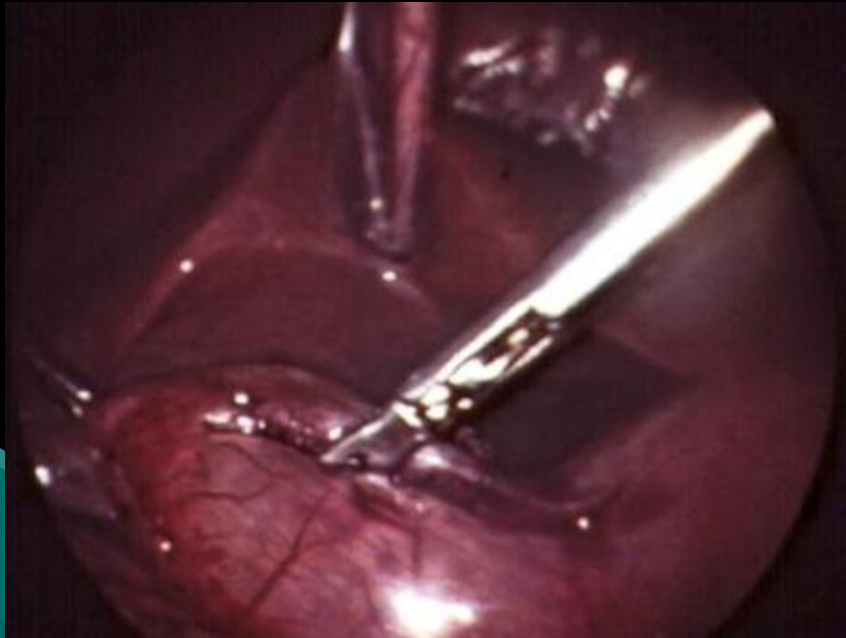


Infantile Hypertrophic Pyloric Stenosis

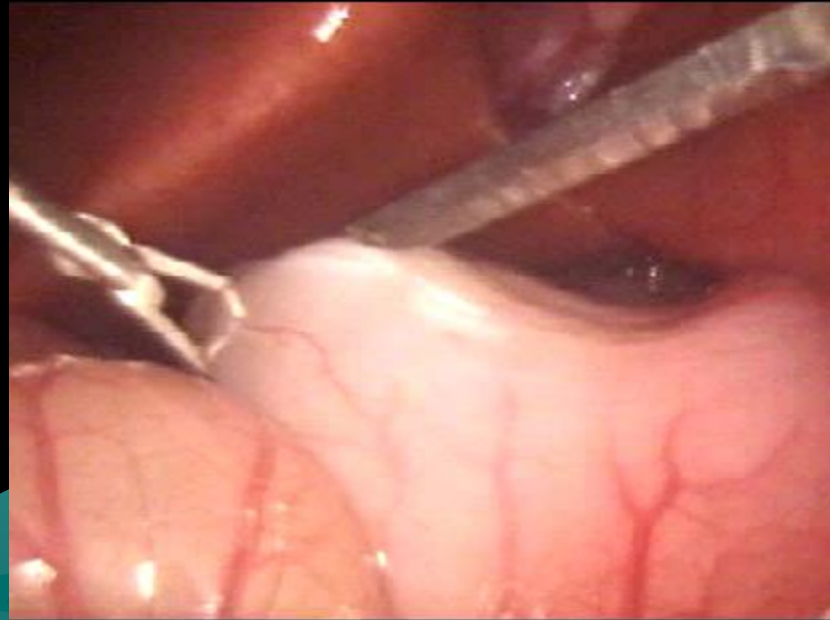
- A 5-mm laparoscope is inserted at the umbilicus.
- A 2-mm forceps with teeth is inserted in the right and left upper abdomen
- The pylorus is incised with a 1.7-mm monopolar scalpel, which coagulates while cutting



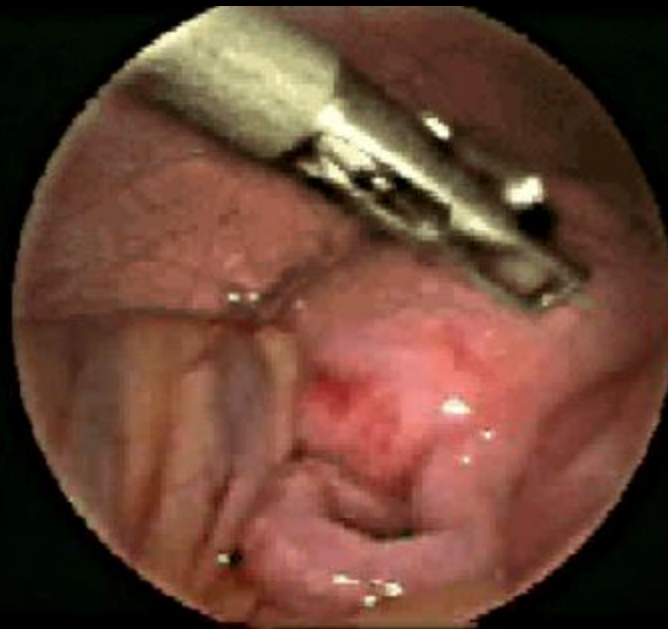Infantile Hypertrophic Pyloric Stenosis



Infantile Hypertrophic Pyloric Stenosis



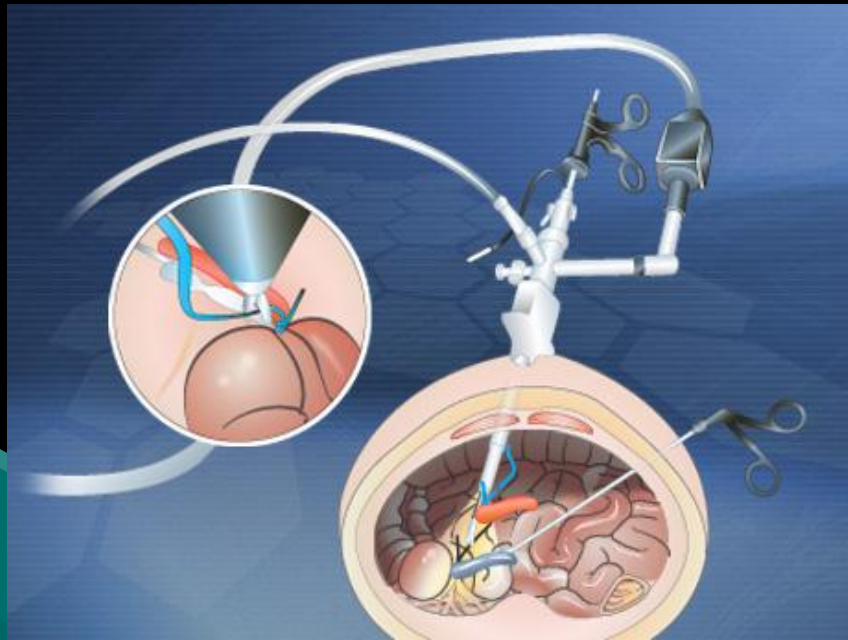
Intestinal Intussusception



Laparoscopic treatment of intussusception works in roughly 50% of paediatric patients



Appendicitis



Chron's disease

Simultaneous Coloscopy and Laparoscopy for Crohn's Disease in Children


F. Schier, S. v. Bismarck, G. Kähler



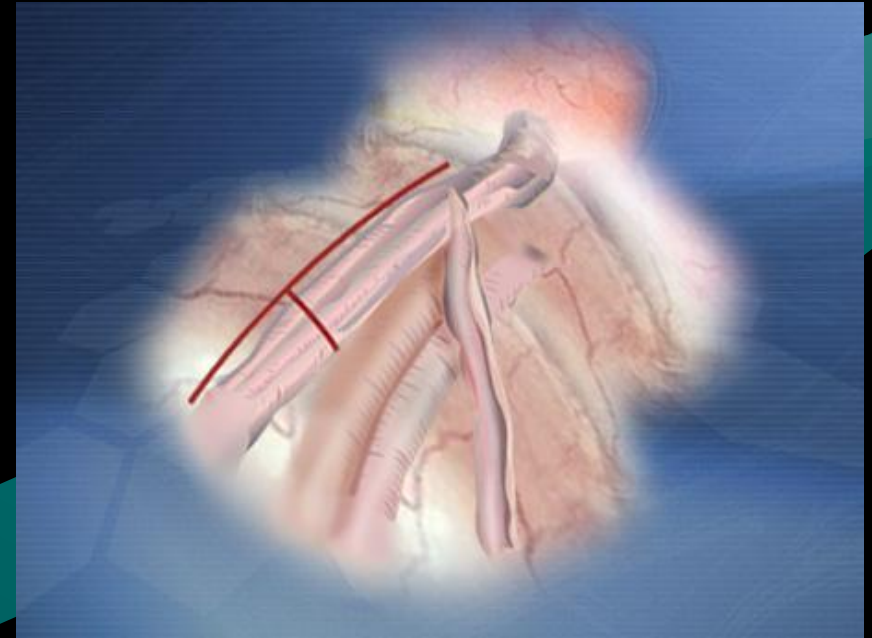
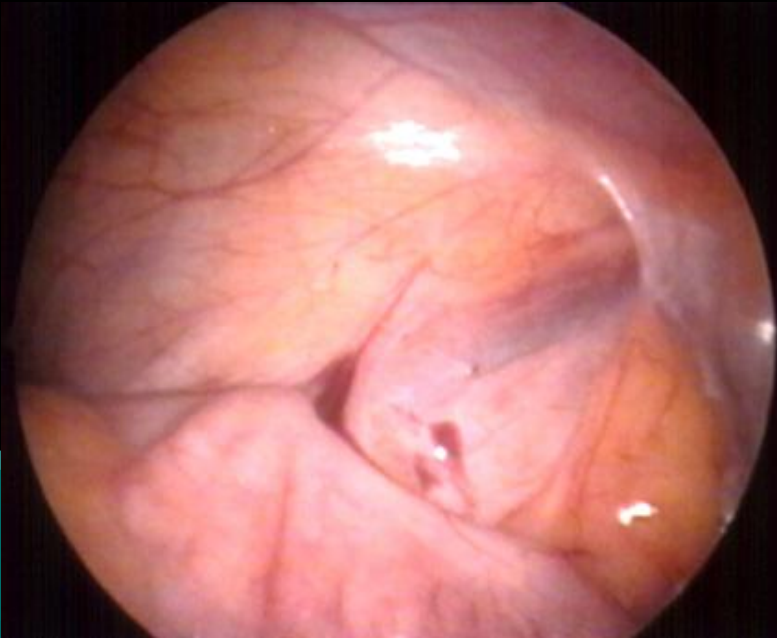
Adhesiolysis



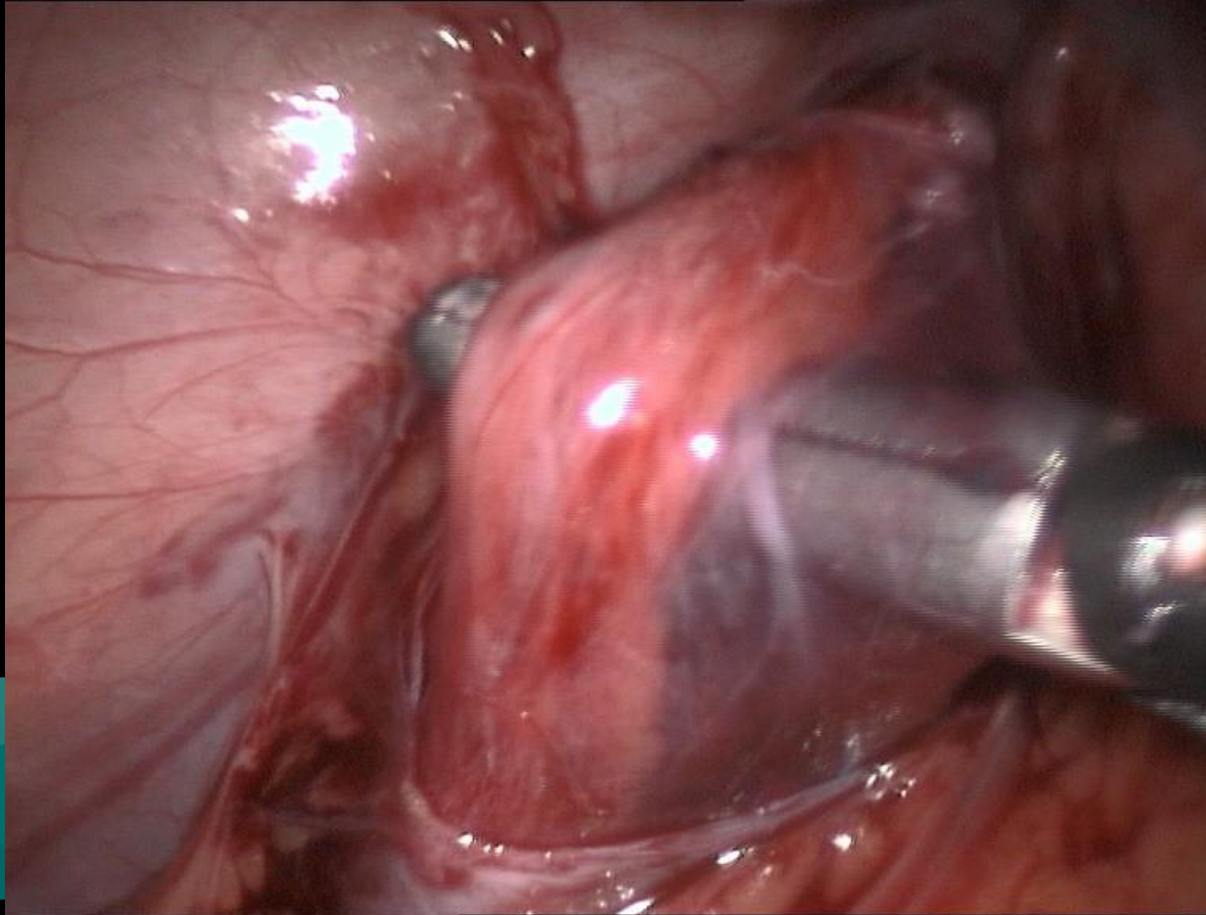
Inguinal Hernia



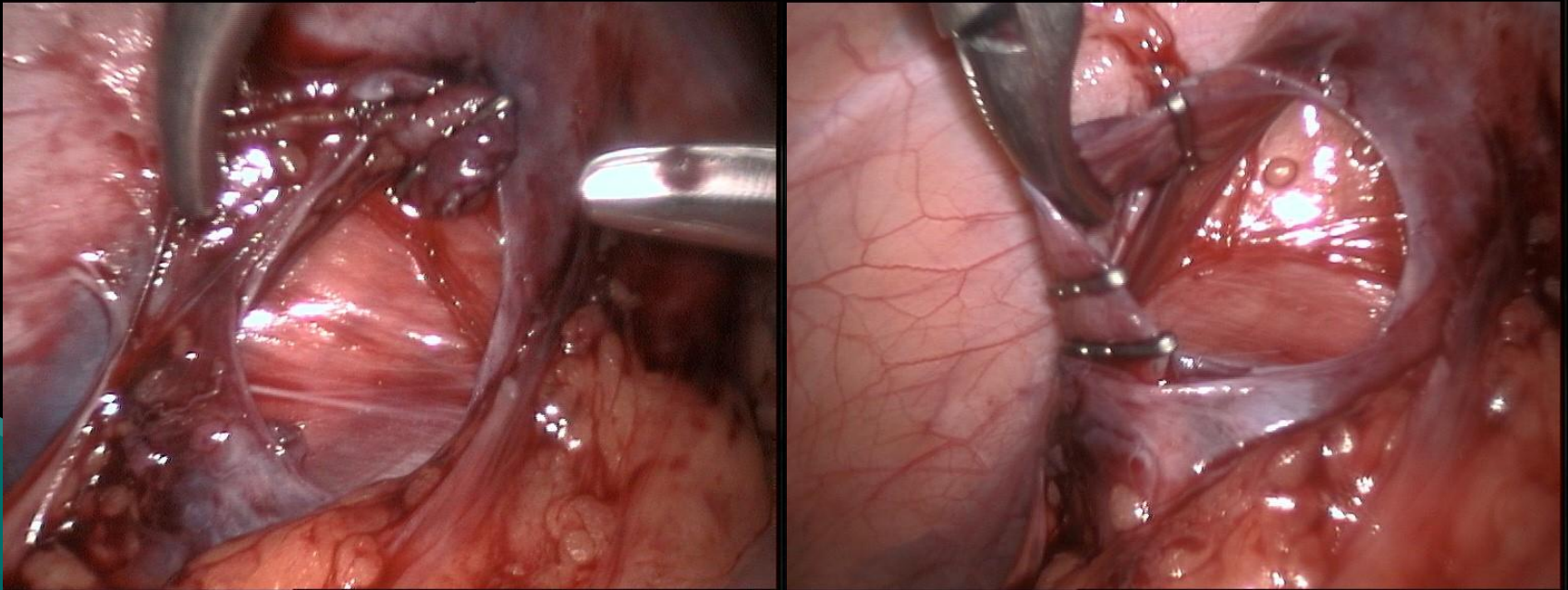
Varicocele



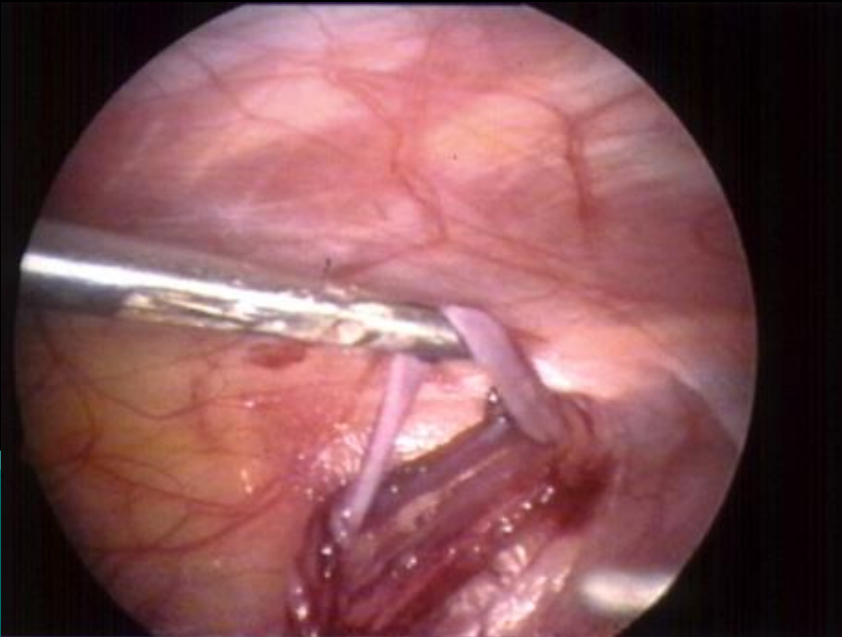
Varicocele



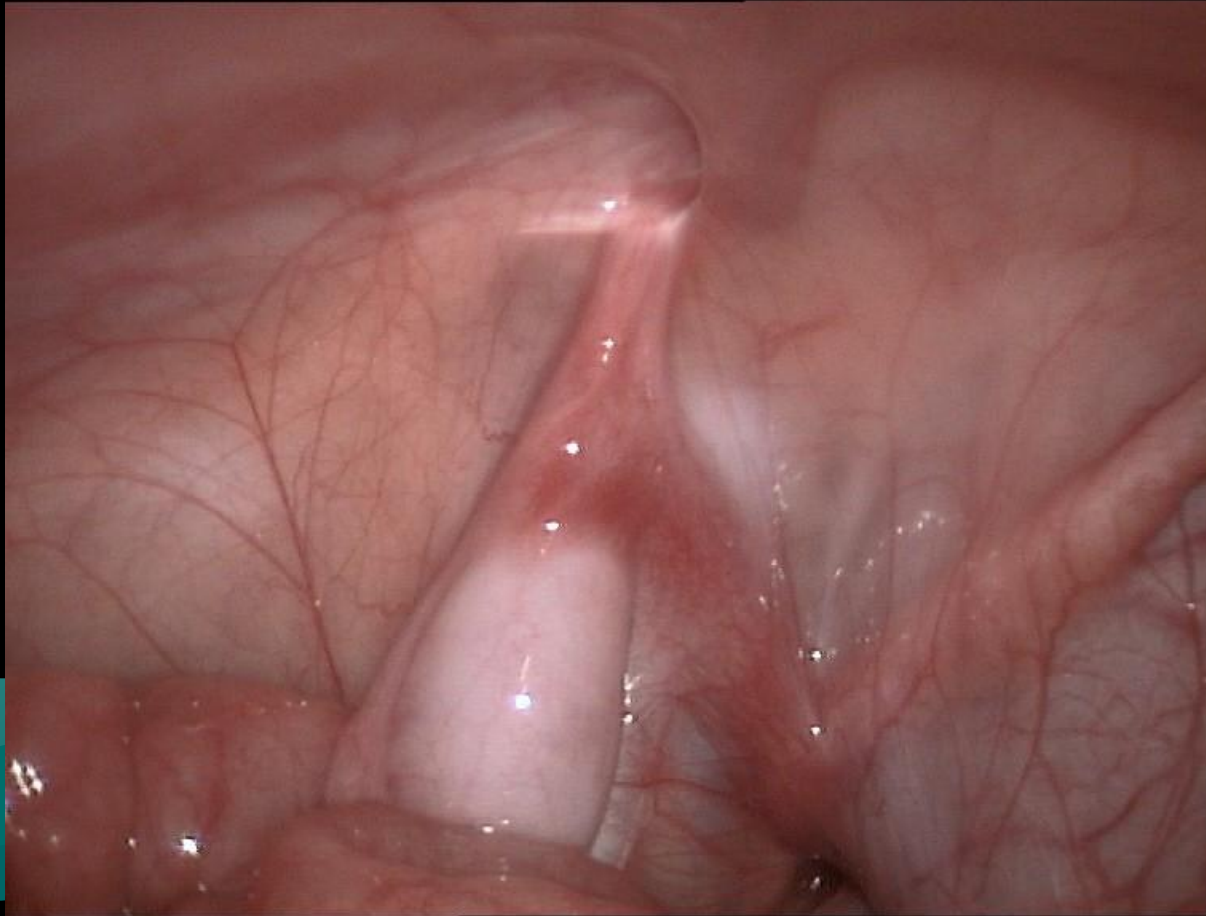
Varicocele



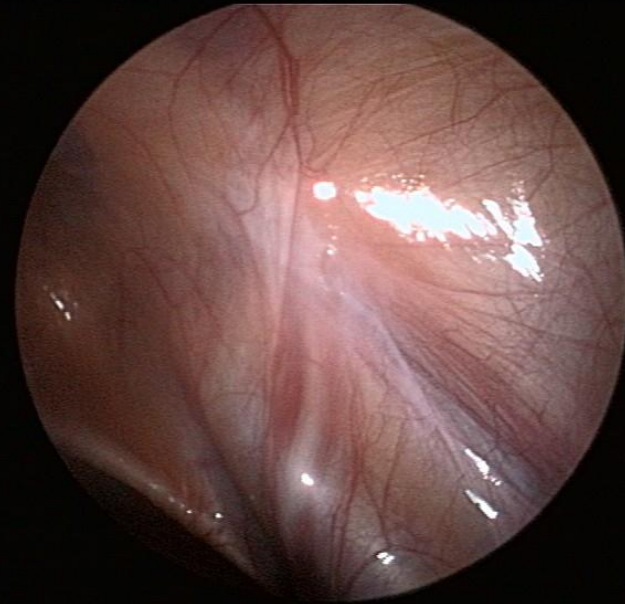
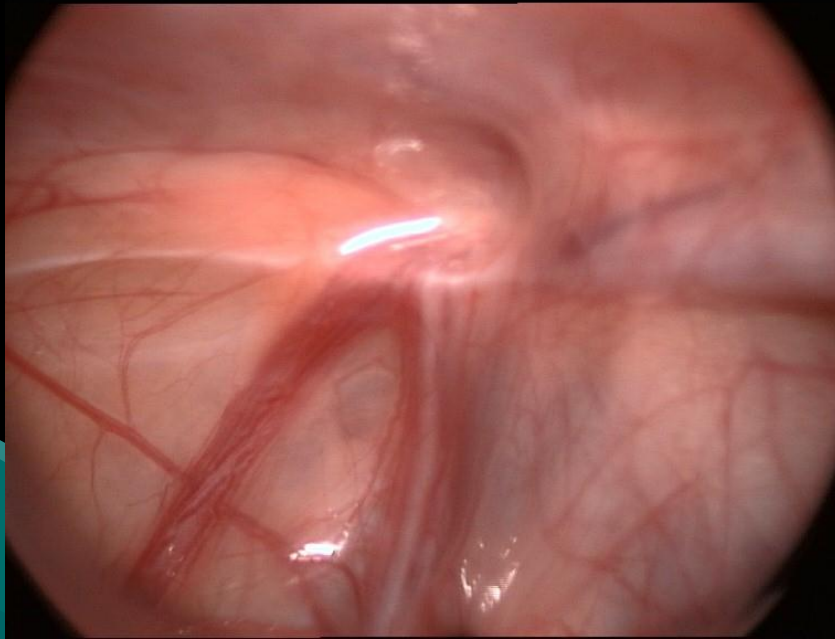
Varicocele



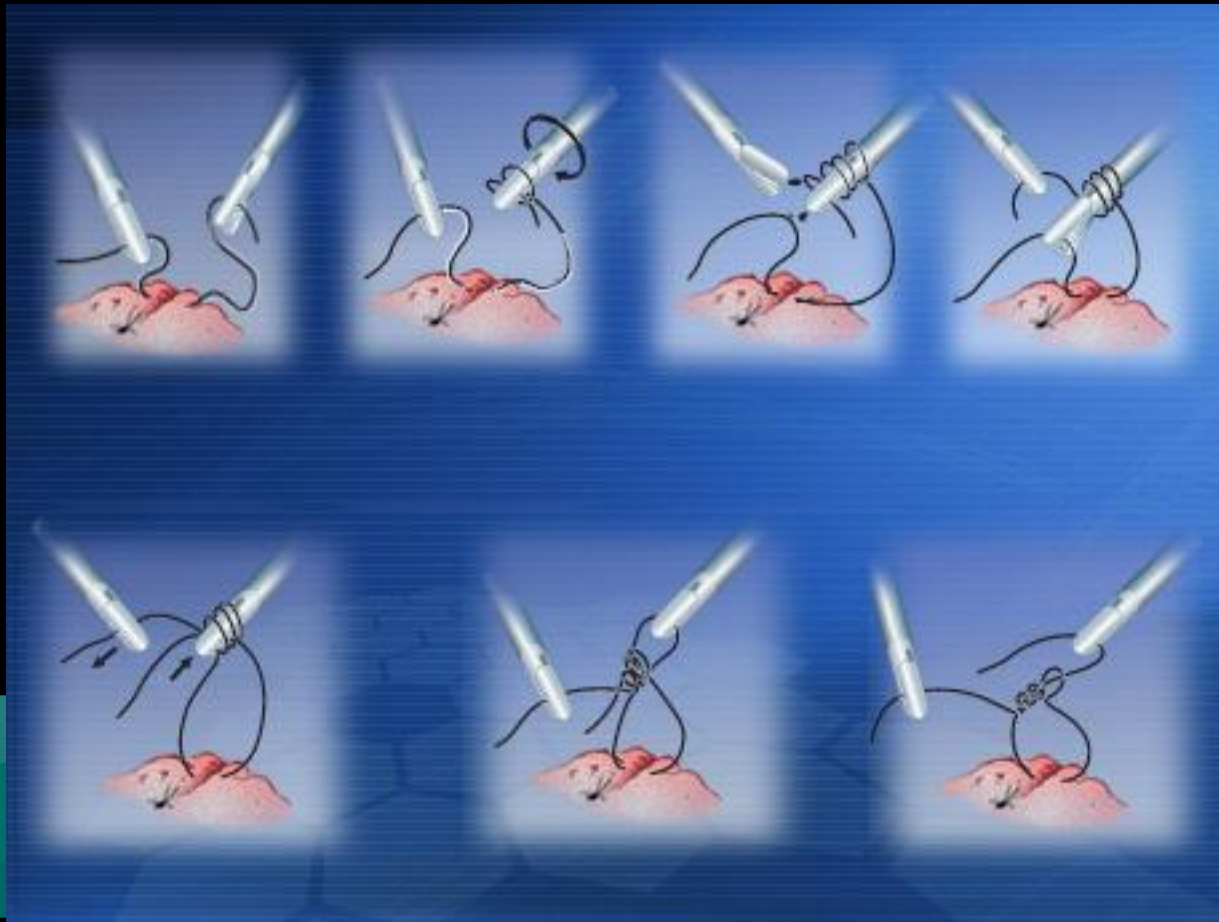
Intra-abdominal Testes



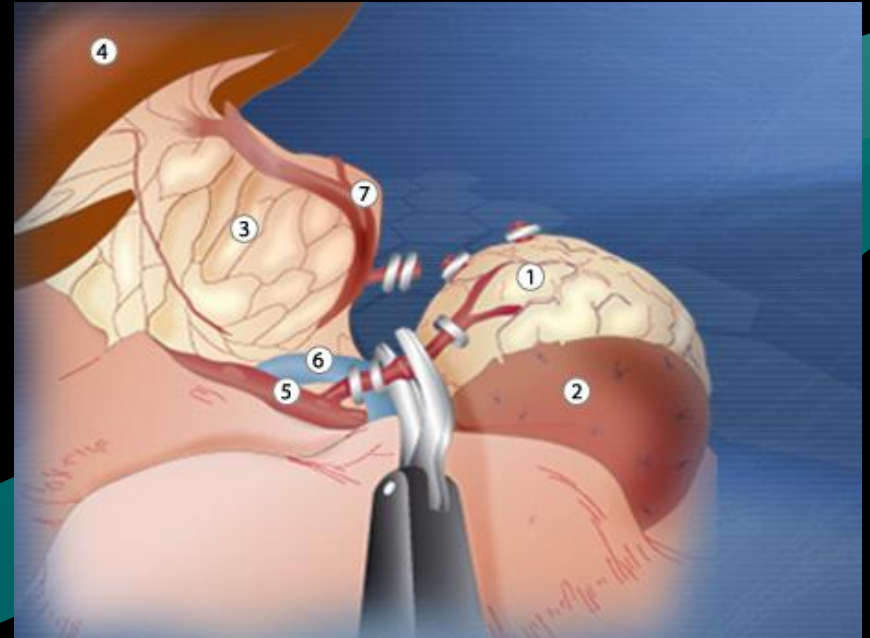
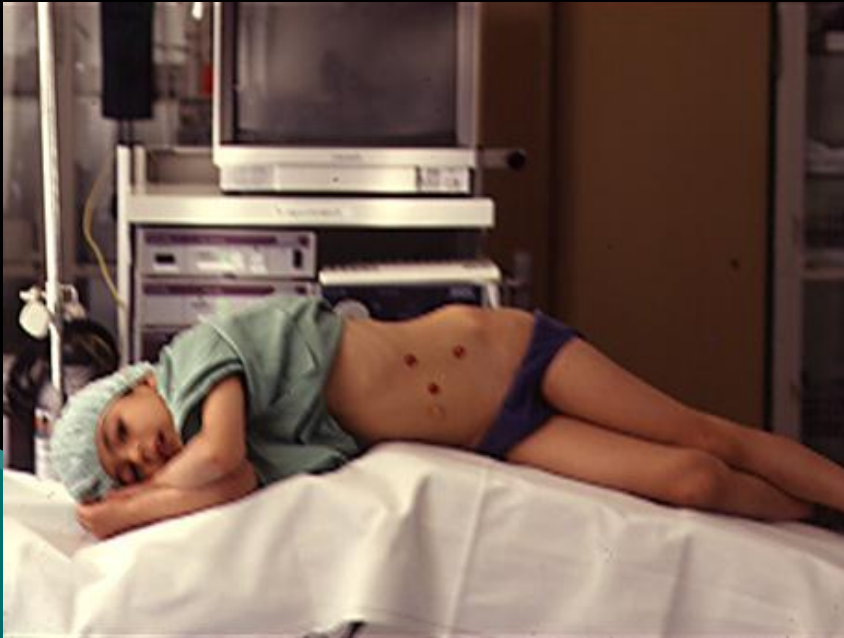Vanished Testes



Suturing in Neonate

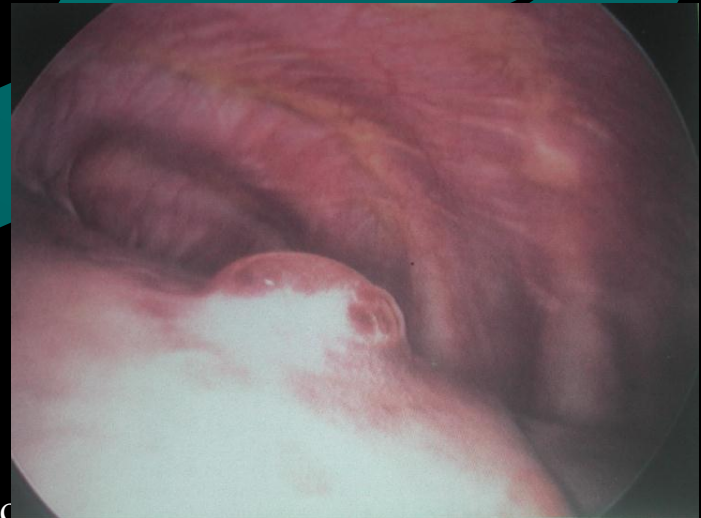
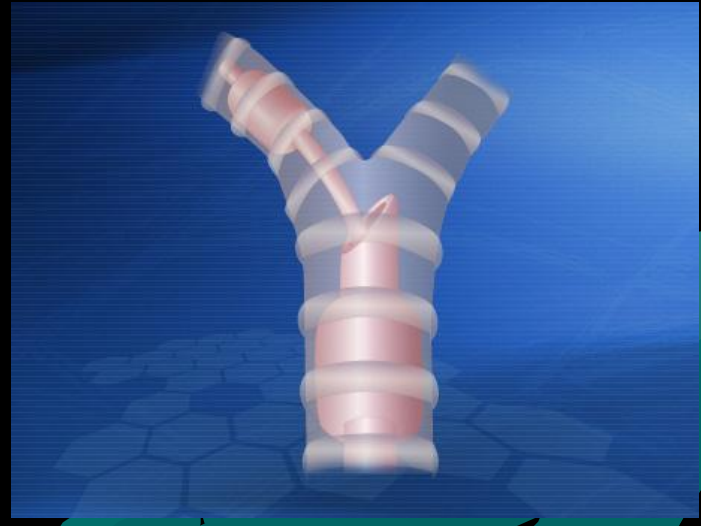

Nephrectomy



Thoracoscopy

The affected lung is collapsed, allowing to start the required procedure for the treatment of pneumothorax.



Advantages of controlled ventilation with single lung ventilation

- No secretions or blood can enter the contralateral lung
- Optimal surgical visualization
- Optimized gas exchange (apneic oxygenation) is a prerequisite
- Bronchoscopy (check tube position, evacuate pus and blood)



Diagnostic Thoracoscopy

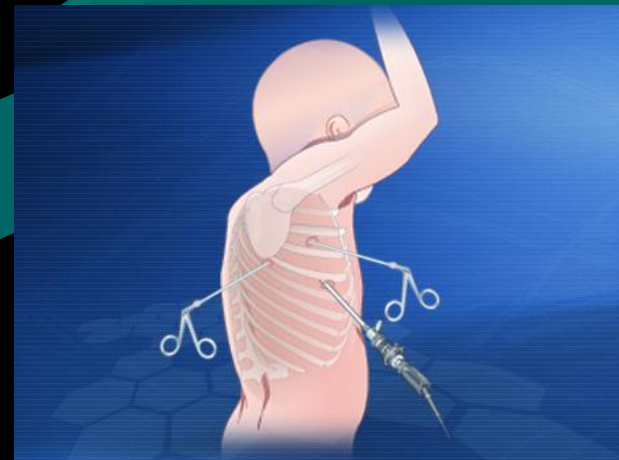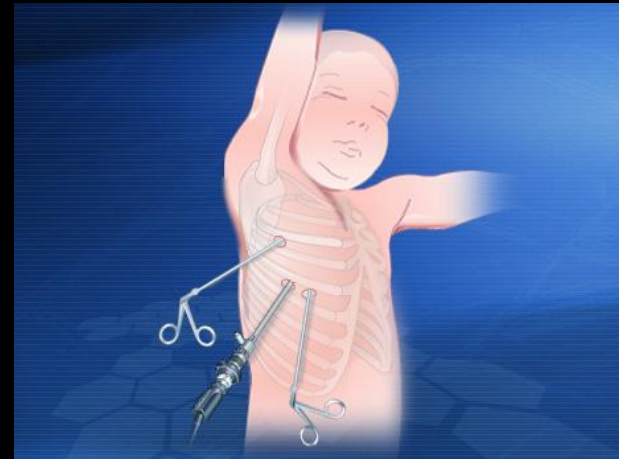The most common indications for pediatric thoracoscopy are for diagnosis of mediastinal masses and lung biopsy for benign diseases.



Diagnostic Thoracoscopy

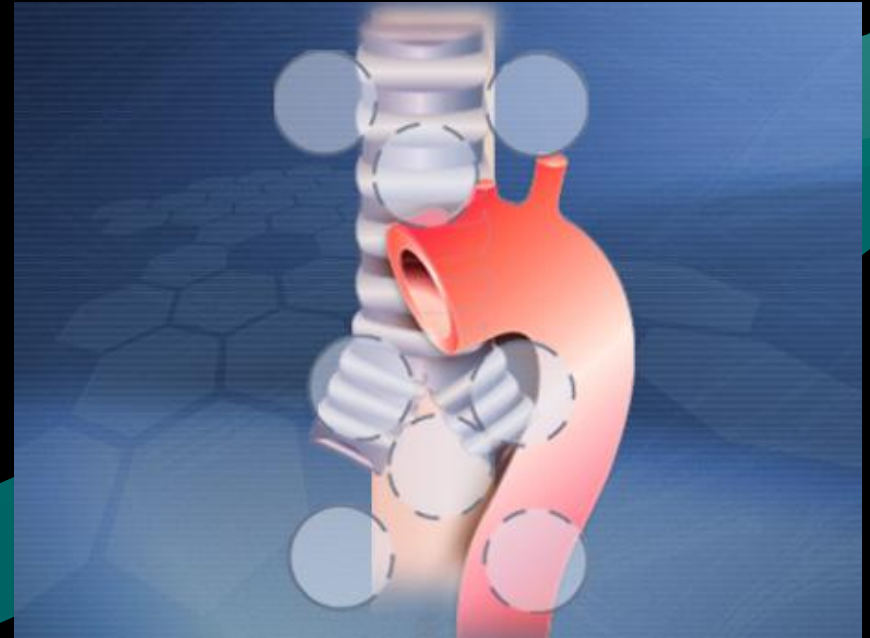
Port Position

- The position of the patient depends on the target area of the mediastinum or lung
- Insufflate CO₂ up to 6 mm Hg, using a flow pressure of 0.3 l/min.
- Over-aggressive insufflation may result in bradycardia.



Bronchogenic Cysts

- Bronchogenic cysts of the lung originate from abnormal budding of the tracheal diverticulum.
- Clinical symptoms are those of airway compression.
- Simple aspiration of bronchogenic cysts is ineffective, because they contain elements of the normal bronchial wall such as bronchial glands, smooth muscle, or nests of cartilage, which usually lead to recurrence of the [Cuyper 1996].
- Resecting the cysts is the treatment of choice



Bronchogenic Cysts



Thoracic Teratoma

- Thoracic teratomas are usually located in the anterior mediastinum, although some may originate posteriorly
- As the phrenic nerve often crosses the tumor, the nerve must be closely monitored during the procedure.
- Nearly all teratomas rupture during the operation, and are eventually removed within a bag through the lowest and most posterior incision.

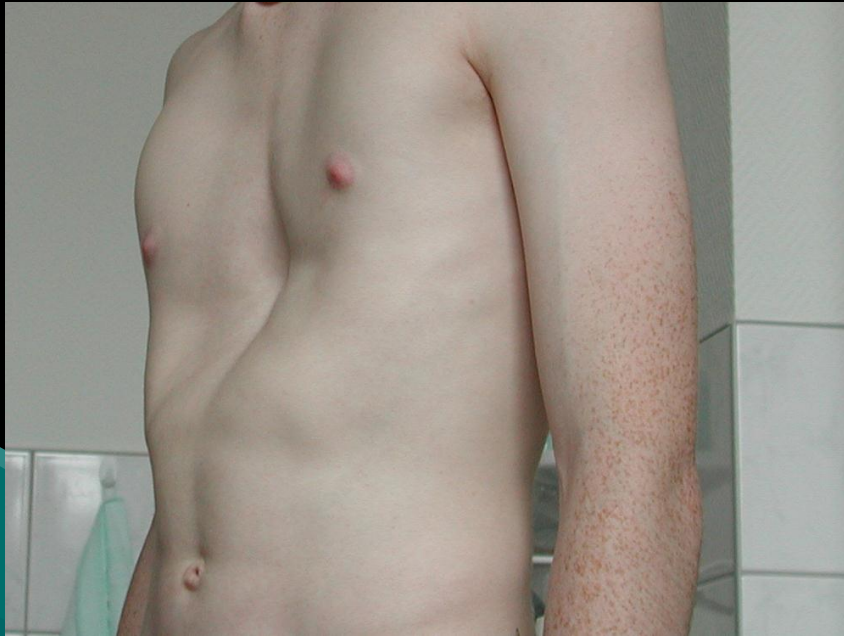

Hyperhidrosis

- For hyperhidrosis of the hands only, coagulate ganglia T2 and T3.
- For the axillae, coagulate ganglion T4.
- The ganglia are easily identified as white, cord-like structures crossing the paravertebral ribs.
- Destroying ganglion T1 results in Horner's syndrome.



Pectus excavatum



STADE, ROBERT

25.06.84

28-AUG-2000

14:08:11.16

TP -258.0

IMA 28

SPI 3

FRANZ.HOSP. HARDERBERG

SOMATOM PLUS 4

VB40C

H-SP-CR

R

kV 140
mA 206
TI 0.75
GT 0.0
SL 8.0/12.0
342 -9/-35
AB40 L0
401S030

NATIV
DR. STADE

W 400
C 60

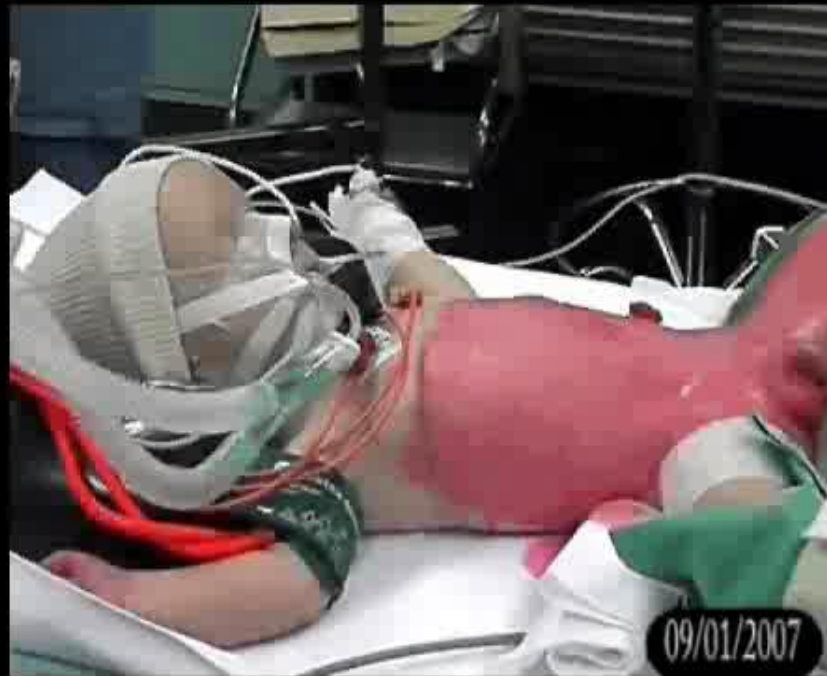A common chest wall deformity in children



Ovarian cysts



Imperforated Anus



Paediatric Oncology

Laparoscopy and
Thoracoscopy has a
good role in
Paediatric Oncology
for Diagnosis of
Metastasis.

Lymphoma



Thank You

