



Retrograde trans-mesoappendicular selective subserosal laparoscopic appendicectomy

Omar Nasher, Ramnik V. Patel, Shailinder J. Singh*

Department of Paediatric Surgery, Queen's Medical Centre, Nottingham University Hospital NHS Trust, Derby Road, Nottingham NG7 2UH, UK

ARTICLE INFO

Article history:

Received 25 January 2013

Received in revised form

8 February 2013

Accepted 9 February 2013

Key words:

Appendicectomy

Laparoscopy

Paediatric

Appendicular mass

Retrograde

Recurrent appendicitis

Subserosal

ABSTRACT

Pediatric laparoscopic appendicectomy in the presence of an appendicular mass following recurrent appendicitis can represent an operative challenge. To address this problem, we describe a laparoscopic technique, which involves a retrograde appendicectomy combined with trans-mesoappendicular and selective subserosal dissection thus preventing the possible damage to the surrounding anatomical structures. This technique has been reported in open appendectomy. However, to the best of our knowledge, it has never been described using the laparoscopic approach.

© 2013 Published by Elsevier Inc. Open access under [CC BY-NC-ND license](http://creativecommons.org/licenses/by-nc-nd/3.0/).

Acute appendicitis is the most common abdominal emergency in the pediatric population accounting for 80% of all the emergency surgical procedures [1,2]. It can sometimes present with an appendicular mass and in this case it is safe and preferable to adopt the policy of treating it non-operatively [3]. Iatrogenic injury to internal organs during difficult open or laparoscopic appendicectomy has been reported in children [4]. This is one of the reasons for conservative treatment of an appendicular mass. However, there are some instances where the mass is discovered intraoperatively making the surgery more challenging. Surgeons have performed open retrograde appendicectomy with or without subserosal dissection in some of these difficult cases [1,5]. We describe a laparoscopic technique, which involves retrograde appendicectomy with subserosal dissection. This novel approach allows successful completion of the operation minimizing the risk of damage to surrounding anatomical structures.

1. Case report

A 15-year-old boy was admitted to our hospital with a 2-day history of constant right iliac fossa pain, which was 6/10 in severity.

It was aggravated by movements and ameliorated by analgesia. He had a previous similar episode of suspected appendicitis, which occurred about 4–6 years ago and was treated conservatively at a different hospital.

On examination, he was afebrile and his observations were all stable. His abdomen was tender on deep palpation in the right iliac fossa. There was no palpable abdominal mass. The patient's white cell count (WCC) was $10.10 \times 10^9/L$ with $8.4 \times 10^9/L$ neutrophils and C-reactive protein (CRP) was 19 mg/L. All the other laboratory results which included liver function test, urea and electrolytes, amylase and lipase were within normal range. It was not a clear clinical picture of appendicitis. Therefore, the child was admitted for close observation. On the next day of his hospital stay, the abdominal pain did not improve and he had guarding in the right iliac fossa. At that time, a provisional diagnosis of appendicitis was made and we decided to proceed surgically.

At laparoscopy, an acutely inflamed and perforated appendix was seen along with free pus in the pelvis and right paracolic gutter. In addition, an inflammatory mass composed of small bowel loops, omentum, terminal ileum and cecum was found in the right lower quadrant of the abdomen. The mass was dismantled with careful laparoscopic dissection to expose the inflamed appendix. This was pelvic in position and also firmly stuck to the right lateral pelvic wall more distally with a gangrenous tip. No obvious faecolith was found.

* Corresponding author. Tel.: +44 115 924 9924; fax: +44 116 289 3395.

E-mail address: shailinder@ntlworld.com (S.J. Singh).

Due to the remarkable difficulties in separating the adhesions in the distal part of the appendix, a classical retrograde appendectomy with laparoscopic approach was commenced. The less inflamed looking base of the appendix was dissected, transected and then stitched with intracorporeal laparoscopic 2–0 vicryl suture. Despite having attempted the classical (extraserosal) retrograde approach laparoscopically, the dense adhesions between appendix and the surrounding retroperitoneal anatomical structures (right vas deferens, ureter and iliac vessels) made the dissection on that plane unsafe.

To overcome this pathological adversity, the subserosal plane was entered in order to remove the appendix avoiding accidental injury to these structures. We could clearly visualize the plane between two leaves of the mesoappendix close to the appendicular base and this enabled us to dissect the appendix subserosally and circumferentially using bipolar diathermy (Fig. 1). This trans-mesoappendicular approach provided better access and the appendicular vessels were cauterized using bipolar diathermy. However, the distal part was still firmly stuck and at this stage the procedure was continued extraserosally in order to safely dissect the gangrenous tip. There was no bleeding from the remaining serosal layer. After removal of the appendix, the peritoneal cavity was thoroughly washed with 0.9% sodium chloride.

The patient's post-operative period was uneventful and he made a smooth recovery. Histopathology confirmed the presence of a pyogenic necrotizing appendicitis with serositis and florid suppuration in the adjacent connective tissue.

2. Discussion

There are divergent opinions on the management of an appendicular mass. In case of a difficult appendicular mass, initial

conservative management followed by interval appendectomy was proposed by Ochsner and Sherren back in 1901 and it is still preferred by many surgeons nowadays. This modality of treatment is thought to decrease the risk of surgical complications and also to avoid recurrence, which may happen once the acute inflammatory process terminates following medical treatment [6].

On the other hand, there is a school of thought in favor of immediate appendectomy in the presence of an appendicular mass as opposed to initial conservative treatment followed by interval appendectomy. In a prospective, non-randomized study conducted on 46 patients who presented with an appendicular mass and underwent surgery within 24 h from admission, difficulties in adhesiolysis and localization of the appendix were recorded only in 10% of the cases and no major complications occurred [7]. Another recent retrospective study, which included 47 patients with an appendicular mass showed that 80.9% of the cases which underwent immediate appendectomy had no complications [8]. Both these studies, advocate the immediate surgical approach to be safe and an effective alternative to conservative management [7,9].

In the absence of appendicular perforation, the mucosa and submucosa are the first tissue layers to be affected as a result of the compromised vessels, leaving the serosal layer intact [1,10]. Therefore, our modality of removing the appendix by dissecting it from the serosal layer does not cause complications that could follow incomplete appendectomy where part of the diseased organ is left in situ. This novel technique was described as subserosal appendicular stripping by Sebastian et al. in a study that included 49 patients who presented with recurrent appendicitis and underwent delayed open appendectomy. Similarly, in their study the appendix was highly inflamed and stuck with numerous serosal adhesions. There were no surgical complications apart from one case of minimal serosal bleeding which was successfully managed with cauterization. All patients were discharged 48 h post-operatively and their routine follow up at three months was uneventful [1]. In our case, we limited the subserosal technique only to the main body of the appendix, which was densely adherent to the right pelvic structures, as opposed to a complete subserosal open appendectomy.

Recently, Hannan and Hoque have described a laparoscopic submucosal appendectomy for difficult and adherent cases to minimize complications in 19 pediatric patients [11]. They used submucosal method similar to Soave pull-through technique for Hirschsprung's disease [12]. However, we among other authors believe that appendicitis is a disease primarily affecting the mucosal layer [1,10]. They also used anti-mesenteric approach to initiate the dissection while we preferred Bianchi's 'triangle of dissection' between the two leaves of the mesoappendix to facilitate dissection in the bloodless plane [13].

To the best of our knowledge, this technique has not yet been described in the Pediatric literature using the laparoscopic approach for the management of an appendicular mass found intraoperatively when performing immediate appendectomy.

3. Conclusion

Recurrent appendicitis after initial conservative treatment may present a difficult and challenging complexity of diagnosis and surgical management. Retrograde trans-mesoappendicular selective subserosal laparoscopic appendectomy when the appendix is stuck and located in the retroperitoneal space could represent the preferred surgical approach as opposed to traditional total extraserosal laparoscopic appendectomy in children. This technique allows the operating surgeon to perform the dissection in a safe plane away from vulnerable retroperitoneal anatomical structures

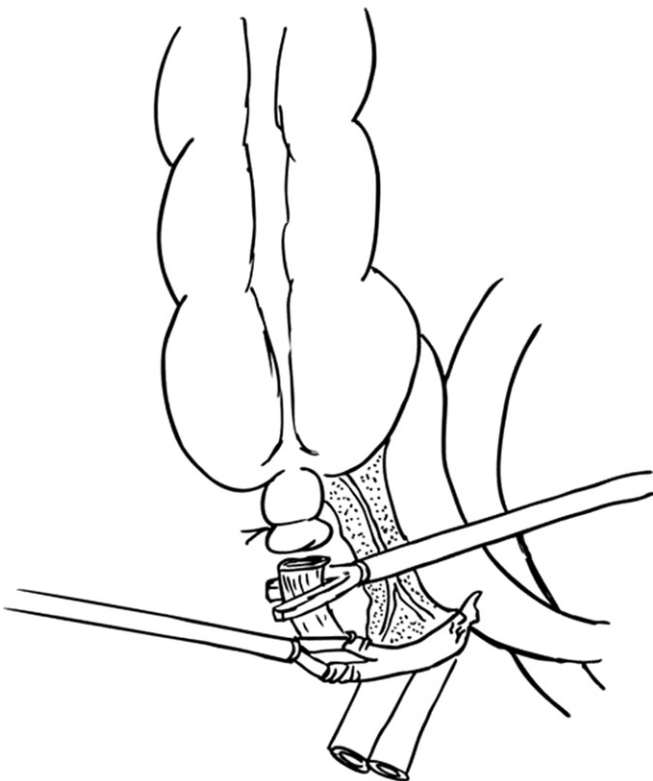


Fig. 1. Laparoscopic selective subserosal appendicular dissection to separate the appendix from the right pelvic structures.

which might be injured during the procedure, minimizing the risk of iatrogenic intraoperative complications.

Acknowledgments

We are very grateful to Mr. Graham Love, the Queen's Medical Centre University Hospital medical illustrator and photographer, for his contribution to the illustration.

References

- [1] Sebastian RT, Philip J, Dutta Roy S, Sebastian VJ. Subserosal appendicular stripping. *Int J Surg* 2007;5(2):86–8.
- [2] Siegel MJ. Acute appendicitis in childhood: the role of US. *Radiology* 1992; 185(2):341–2.
- [3] Surana R, Puri P. Appendiceal mass in children. *Pediatr Surg Int* 1995;10(2–3): 79–81.
- [4] Dalecki J, Patel R, Sundararajan L. Ureteral damage during appendectomy. *J Pediatr Surg* 2010;45(11):e11–3.
- [5] Bakti N, Hussain A, El-Hasani S. A rare complication of acute appendicitis: superior mesenteric vein thrombosis. *Int J Surg Case Rep* 2011; 2(8):250–2.
- [6] Cunnigaiper ND, Raj P, Ganeshram P, Venkatesan V. Does Ochsner-Sherren regimen still hold true in the management of appendicular mass? *Ulus Travma Acil Cerrahi Derg* 2010;16(1):43–6.
- [7] Bahram MA. Evaluation of early surgical management of complicated appendicitis by appendicular mass. *Int J Surg* 2011;9(1):101–3.
- [8] Kaya B, Sana B, Eriş C, Kutaniş R. Immediate appendectomy for appendiceal mass. *Ulus Travma Acil Cerrahi Derg* 2012;18(1):71–4.
- [9] Malik AM, Shaikh NA. Recent trends in the treatment of the appendicular mass. In: Lander A, editor. *Appendicitis – A Collection of Essays From Around the World*. InTech; 2012. p. 87–94.
- [10] Crowley LV. The gastrointestinal tract. In: Crowley LV, editor. *Essentials of Human Disease*. Jones and Bartlett Publishers; 2011. p. 408.
- [11] Hannan J, Hoque M. Laparoscopic submucosal appendectomy for difficult and adherent cases: a novel technique to minimize complications. *J Laparoendosc Adv Surg Tech A* 2012;22(10):1017–20.
- [12] Soave F. Hirschsprung's disease: technique and results of Soave's operation. *Br J Surg* 1966;53(12):1023–7.
- [13] Bianchi A. Intestinal lengthening: a technique for increasing small bowel length. *J Pediatr Surg* 1980;15:145–51.