

Pediatric Minimally Invasive Surgery: Laparoscopy and Thoracoscopy in Infants and Children

AUTHORS: Thane Blinman, MD,^a and Todd Ponsky, MD, FACS^b

^aChildren's Hospital of Philadelphia, Philadelphia, Pennsylvania; and ^bCase Western Reserve University, Cleveland, Ohio

KEY WORDS

laparoscopy, thoracoscopy, surgery, neonate

ABBREVIATIONS

MIS—minimally invasive surgery

NOTES—Natural orifice transluminal endoscopic surgery

www.pediatrics.org/cgi/doi/10.1542/peds.2011-2812

doi:10.1542/peds.2011-2812

Accepted for publication Apr 20, 2012

Address correspondence to Thane Blinman, MD, Children's Hospital of Philadelphia, 34th and Civic Center, Philadelphia, PA 19083. E-mail: blinman@email.chop.edu

PEDIATRICS (ISSN Numbers: Print, 0031-4005; Online, 1098-4275).

Copyright © 2012 by the American Academy of Pediatrics

FINANCIAL DISCLOSURE: *The authors have indicated they have no financial relationships relevant to this article to disclose.*

FUNDING: No external funding.

abstract

This article discusses the potential benefits and challenges of minimally invasive surgery for infants and small children, and discusses why pediatric minimally invasive surgery is not yet the surgical default or standard of care. Minimally invasive methods offer advantages such as smaller incisions, decreased risk of infection, greater surgical precision, decreased cost of care, reduced length of stay, and better clinical information. But none of these benefits comes without cost, and these costs, both monetary and risk-based, rise disproportionately with the declining size of the patient. In this review, we describe recent progress in minimally invasive surgery for infants and children. The evidence for the large benefits to the patient will be presented, as well as the considerable, sometimes surprising, mechanical and physiological challenges surgeons must manage. *Pediatrics* 2012;130:539–549

Until recently, minimally invasive surgery (MIS) in children occupied only the fringes of pediatric surgical interventions. Trailblazers like Rothenberg, Georgeson, Holcomb,¹ and others adapted MIS methods for infants and small children in the late 1990s and early 2000s, reporting small series of novel operations with good results (eg, refs 2–4). Others had reported adaptation of MIS methods to children earlier than these surgeons,^{5–9} but what distinguished the efforts of successful trailblazers was not their novelty, but their pedagogy. Several declared that something could be done; few could demonstrate in detail and teach others how to do these operations well (Fig 1).

Although children worldwide routinely benefit from expert application of MIS, most pediatric procedures do not use advanced minimally invasive methods. Although most offer laparoscopic appendectomy, in a recent large survey¹⁰ of pediatric MIS practices worldwide, surgeons reported that just about one-third perform laparoscopic pyloromyotomy for pyloric stenosis, and only 11% of respondents recommend the approach. For more complex procedures, the numbers are even lower. Fewer than one-fifth offer laparoscopic

Ladd's for malrotation, and fewer than one-tenth have attempted laparoscopic repair of choledochal cyst. Despite the growth in application of MIS to pediatric surgical disease in the past decade, most pediatric surgeons in practice today rely largely on standard open technique for procedures less common than fundoplasty, and even here many or even most pediatric surgeons report that they do not recommend MIS.¹⁰ Minimally invasive methods may have left the fringes of pediatric surgical practice, but they do not yet stand in the center.

Why not? In this review, we describe recent progress in applying MIS to infants and children. Most reviews of minimally invasive methods focus only on the advantages offered by these new techniques. Benefits can be substantial: wound, technique, speed, cost, length of stay, information. But none of these benefits comes without costs or risks, difficulties that appear to escalate disproportionately with the declining size of the patient. The evidence for benefits to the patient are presented, as well as the considerable, sometimes surprising, mechanical and physiologic challenges surgeons must manage for safe, successful procedures.

WHAT IS MIS?

MIS is the common term for a collection of surgical techniques that aim to circumvent the morbidity and limits of “conventional” open surgery. Historically, it has gone by other names: keyhole surgery, band-aid surgery, scarless surgery. Some of its champions prefer Minimal Access Surgery.¹¹ MIS was really an informal name, maybe even a marketing term like keyhole surgery, not a technical description, but it is the name that has stuck, and will be the term we use here.

In general pediatric surgery, MIS refers to operations in the chest, (“thoracoscopy”), and in the abdomen, (“laparoscopy”). (Urological procedures in children are also done laparoscopically, but will not be considered here; see Passerotti and Peters¹² and Sweeney et al.¹³) The elements of MIS include the telescope, trocars, long instruments, carbon dioxide insufflation to create a working space, and modified surgical technique. In pediatric MIS, all of these elements are modified still further, and although the names are the same, the geometries and methods have important differences. These differences are often, but not always, quantitative modifications of historical inventions. The first use of laparoscopy in general surgery was not until 1985, when Eric Muhe described a laparoscopic cholecystectomy.¹⁴ Driven both by patient demand and by the invention of charge-coupled-device video technology, laparoscopic cholecystectomy replaced the open approach as the standard of care in <10 years. Then followed an explosion of laparoscopic and thoracoscopic procedures in general surgery. While MIS was gaining popularity in the adult population, pediatric surgeons resisted adopting these techniques in children. Although some resistance was epistemological,¹⁵ much was technological: the early years of the laparoscopic revolution offered only large

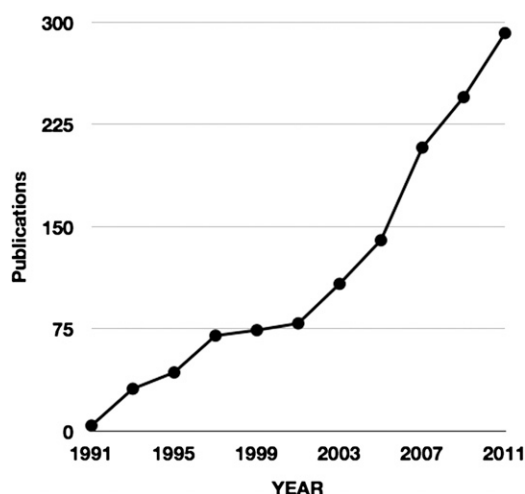


FIGURE 1 Number of publications in PubMed containing the title word “laparoscopic” and the keyword “pediatric” by year of publication. Broad application of minimally invasive techniques in children is a recent development, and still in progress.

(10-mm diameter) telescopes and instruments, clunky endomechanical devices (eg, trocars and staplers), and relatively unsophisticated CO₂ insufflators.¹⁶ These insufflators delivered large amounts of CO₂ into the abdomen with crude pressure control, creating dangerously high intra-abdominal pressures in small children. Eventually, instrument manufacturers began to offer 5-mm and 3-mm devices and insufflators safe enough for use in small patients. The modern MIS “suite” adds high-definition imaging and other technology, offering the surgeon improved ergonomics and finer control over image, energy, and pressure (Fig 2).

In the mid 1990s, pediatric surgeons began to publish their laparoscopic experience, showing laparoscopy to be a viable alternative for some patients.¹⁷ Echoing the adult experience, MIS in children began with laparoscopic cholecystectomies and laparoscopic appendectomies. Holcomb et al¹⁸ described the first laparoscopic cholecystectomy in a child in 1991, taking nearly 2 hours for each procedure, and even trying a surgical laser in some. The laser has not become a central pediatric MIS tool, but the advantages of the laparoscopic approach were plain. Appendectomy, splenectomy, and Nissen fundoplication soon entered into the pediatric surgeon's

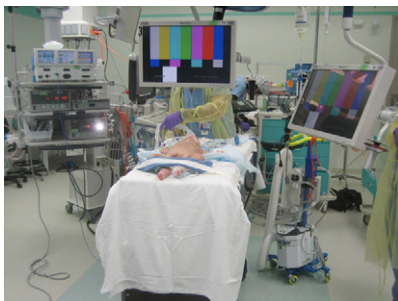

FIGURE 2

The modern minimally invasive suite is distinguished by advanced technology, most of it dedicated to improved imaging; however, new techniques accompany the technology. In this case, the patient is positioned at the foot of the bed, not the middle, and the surgeon stands below the patient's feet, not in the traditional place at opposite sides of the patient.

repertoire. New instruments were more refined (eg, finer tips, stiffer shafts, shorter reaches, less heat spread, better insulation, finer feedback control on energy tools and insufflators, better optics) complementing improved manual skills. Surgeons also invented workarounds for circumstances where technology (eg, endoscopic staplers) had not caught up. This combination of very fine devices, precise movement, and clever workarounds allowed surgeons to attempt minimally invasive procedures on smaller children. When the techniques were applied to infants <28 days old and weighing <5 kg¹⁶ (sometimes much less: procedures in patients <1500 g are feasible), they created the nascent subfield of Neonatal

MIS^{19,20} (Table 1). Now, laparoscopic or thoracoscopic approaches to a large variety of pediatric and neonatal surgical disease have been described (Table 2).

ADVANTAGES OF MIS

Incision Advantages

Incisional morbidities (pain, scar, infection risk, dehiscence, and herniation) depend directly on a wound's closing tension.^{21–28} Recently, it has been demonstrated that wound tension is proportional not to the length of the incision, but to the square of incisional length.²⁹ Consequently, the sum of total tension across all of the small MIS incisions will be a small fraction of the tension

TABLE 1 Milestones in the History of Pediatric MIS

Year	Event
1901	Kelling proposes pneumoperitoneum to observe abdominal organs using a cystoscope “celioscopy.”
1911	Jacobaeus performs diagnostic laparoscopy and thoracoscopy. Berheim uses a proctoscope through the abdominal wall for diagnosis, calling it “organoscopy.” Fervers tries oxygen, CO ₂ , and room air (his preferred).
1929	Kalk introduces a form of spring-loaded needle and trocar setup for insufflation, 30° scope, uses filtered air from a squeeze bulb.
1937	Ruddock (an internist!) reports 500 cases of “peritoneoscopy” with mortality of 0.2%.
1938	Veress invents his needle.
1940s	Fiber optics invented.
1960s	Gynecologists begin using laparoscopy.
1966	Kurt Semm performs first laparoscopic appendectomy. Hopkins Rod-Lens and “cold” light is introduced.
1970	First MIS textbook in America: <i>Laparoscopy, Culdoscopy, and Gynecography</i> by Melvin Cohen (ob/gyn) later called “The Father of Laparoscopy.”
1985	Eric Muhe (Germany) performs first primitive laparoscopic cholecystectomy. First “modern” (4-trocar version) is performed in 1987 by Mouret (France).
1986	Charge-couple device TV marketed by the Circon Corporation.
1988	First laparoscopic cholecystectomy in the United States.
1989	Waldschmidt organizes a meeting in Berlin about lasers in children. This first meeting concerning pediatric MIS set the stage for creation of the International Pediatric Endosurgery Group, the premier pediatric MIS society.
1991	Alain reports first laparoscopic pyloromyotomy.
1991	Holcomb reports first laparoscopic cholecystectomy in a child.
1993	Rothenberg reports first thoracoscopic lung lobectomy in a child.
1994–1995	Willital creates the International Pediatric Endosurgery Group (IPEG). The first official IPEG meeting is held in Orlando, Florida, with Keith Georgeson as the first chair.
1995	Lobe arranges for the proceedings of IPEG to be published as for a supplement to the <i>Journal of Laparoscopic and Advanced Surgical Techniques</i> . This supplement would go on to become the society's own journal <i>Pediatric Endosurgery and Innovative Techniques</i> under the guidance of Lobe as the Editor in Chief.
1999	Lobe and Rothenberg perform the first thoracoscopic pure esophageal atresia repair in Berlin, Germany.
2000	Georgeson describes laparoscopic-assisted anorectal pull-through.
2001	Bax reports first laparoscopic duodenal atresia repair.
2002	Rothenberg reports first thoracoscopic TEF repair.
2009	T. Ponsky reports single-port laparoscopy in children.

TABLE 2 Partial List of Pediatric Conditions and Operations for Which Minimally Invasive Methods Are Used

Appendectomy
Bronchogenic cyst
Choledochal cyst
Cholecystectomy
Colectomy/j pouch
Colonic stricture
Congenital adenomatoid malformation
Congenital diaphragmatic hernia repair
Diaphragmatic placcation
Duodenal atresia
Empyema
Esophageal duplication cyst resection
Gastric duplication cyst resection
Gastrostomy
Heller myotomy (achalasia)
Imperforate anus repair
Inguinal hernia repair
Intussusception resection
Kasai
Ladd's
Lung biopsy
Meckel's
Mesenteric Cyst
Nephrectomy
Nissen, Thal, Toupet, Dor fundoplasty
Oncology: diagnosis and resection
Ovarian pathology
Pancreatectomy
Perforated ulcer repair
Pull-through for Hirschsprung disease
Pyloromyotomy
Sequestration
Splenectomy
Spontaneous pneumothorax
Thymectomy
Tracheo-esophageal fistula
Trauma exploration

across a similar open incision. As an illustration, consider an operation performed with five 5-mm incisions, and an operation in a similarly sized child performed by using a single 25-mm incision. Because closing tension is proportional to some constant C (incorporating lumped tissue mechanical properties) times the sum of the squares of the tensions, the total closing tension for the laparoscopic case will be

$$5*(5^2) \cong 125*C,$$

whereas the incision for the open case will be

$$C*25^2 \cong 625*C.$$

In other words, the patient with the open incision experiences relative tension

fivefold greater. It is this relationship that explains the fallacy committed by those who claim that open incisions are "just the same as all those little incisions added together" when criticizing MIS. Incisions do not sum this way.²⁹

This relationship may explain well-established wound advantages. For example, it has been shown that postoperative pain (and length of stay) is markedly reduced with MIS approaches.³⁰⁻³² Moreover, it has been recently shown that MIS produces a relative risk of wound infection of just 0.27,³³ showing that MIS protects from surgical site infections similar to perioperative antibiotics.³⁴ Similarly, wound dehiscence and hernia are also much less for MIS.³⁵ All of these body wall advantages likely stem from reduction in total closing tension. Meanwhile, this relationship governs the limits and advantages of single-port and needlescopic techniques (see later in this article).

Chest Wall Deformity

These incisional advantages are not confined to the abdomen. Standard posterolateral thoracotomy is an especially painful incision, often requiring long hospital stays, epidural infusions, and relatively large doses of narcotics. Later, the patient is at risk for chest wall deformity and scoliosis,³⁶⁻³⁹ via at least 2 mechanisms. First, division of latissimus and serratus muscles (sometimes with underlying rib resection) may create shoulder girdle instability. Second, tight reapproximation of adjacent ribs creates a tensile component on the lateral chest wall. As the child grows, scoliosis and other distortions of the thoracic cage can manifest, sometimes within months (Fig 3). In contrast, because there are only small incisions between ribs, thoracoscopy cannot create these mechanical distortions.⁴⁰

Intra-abdominal Advantages

The advantages offered by MIS are not confined to the body wall. Another major

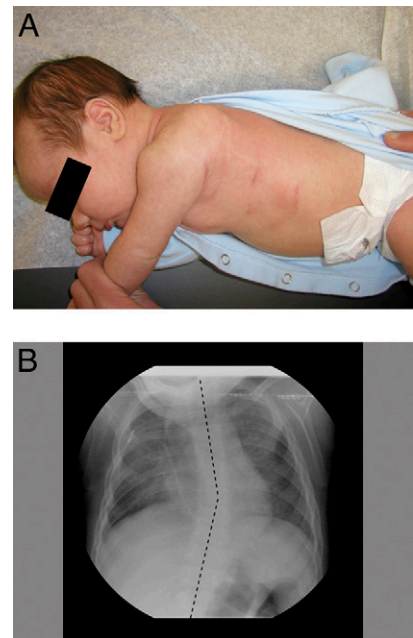


FIGURE 3

A, Thoracoscopy incisions on an infant are nearly invisible 2 weeks after thoracoscopic lobectomy for congenital adenomatoid malformation. B, In contrast, just 8 months after right thoracotomy, marked angulation of the spine (dotted lines) has developed in another infant.

advantage is a reduced propensity to create postoperative adhesions. In particular, MIS produces a tiny fraction of the adhesions as the open approach.⁴¹ The mechanism of this advantage is not proved; but decreased tissue handling, in situ dissection rather than bowel delivery into the wound; and reduced exposure to talc, rubber, or polyisoprene from surgical gloves are posited contributors.

Meanwhile, the surgeon enjoys advantages in visualization and precision. A laparoscopic approach allows better visualization of obscure structures and areas, such as the lower esophageal sphincter complex and the small vagus nerves running along the esophageal muscle. Modern high-definition digital cameras and monitors dramatically magnify these small details, and angled telescopes allow views around corners simply unavailable in open cases. When this visualization is combined with the meticulous precision possible to the

well-practiced MIS surgeon who knows how to “move small,” operations may be completed with similar or superior mechanical results as open cases. For example, authors have reported reductions in both case time and complications for pyloromyotomy, fundoplasty, tracheo-esophageal hernia repair, duodenal-atresia repair, and other cases performed in infants (eg, refs 4, 42, 43).

Cost

That these advantages represent real improvement in pediatric surgical technique is demonstrated by the cost advantage of MIS. For example, a large review comparing open and laparoscopic fundoplication demonstrated that the MIS approach was far less expensive (~\$13 000 for laparoscopic vs >\$22 000 for open). Not counted in this financial reckoning was reduction in risk-based costs: the MIS approach showed a 51% reduction in the risk of any surgical complication.⁴⁴

However, these cost savings are not all realized up front. At first, the need for specialized equipment and extra training of nurses and technicians creates large up-front costs for hospitals introducing MIS.⁵⁰ Once established, however, hospital costs on a per-case basis are generally lower. Still, not all hospitals see this benefit; much appears to depend on the details of specific cases, the skills of the surgeons, and what exactly is counted.^{45–50} More difficult to count are the costs to the patient: What is the added cost of 3 extra days in the hospital on opiates after open surgery? What is the value of not having to see that large scar every day? Health care financing today destroys pricing information, obscuring objective measures of these and other values.⁵¹ Meanwhile, an ironic demonstration of the cost advantage of MIS comes from insurers who, despite the greater technical difficulty of MIS, often offer decreased reimbursement if the operation was performed by using MIS.

Precision

Evidence regarding the effectiveness of MIS compared with open surgery has predictably lagged behind the introduction of new methods.¹⁵ Nevertheless evidence is accumulating regarding the technical integrity of MIS procedures. For many operations, the mechanical result of the procedure is similar or superior to open operations (thymectomy,⁵² duodenal atresia,⁵³ appendectomy,⁵⁴ fundoplasty,^{44,55,56} esophageal atresia⁴). In some cases, however, it is clear that surgeons have more to learn (eg, diaphragmatic hernia⁵⁷). See later in this article.

Speed

Closely related to cost and precision is speed. Not only does longer operating times cost more in terms of operating room resources, but longer cases appear to increase the risk of complications.⁵⁸ The picture for MIS and operating time is mixed. Early in any given surgeon's experience, operating times for laparoscopic cases can exceed the expected time for open procedures. The learning curve is well documented^{43,59–62}; however, as surgeons become more facile, operating times can drop dramatically. For example, laparoscopic pyloromyotomy takes less time than the standard procedure, sometimes far less, but with no “price” of increased complications.⁶³ Adept surgeons can perform fundoplasty in < 1 hour, even in infants weighing ~3 kg. In skilled hands, thymectomy, tracheo-esophageal fistula, duodenal atresia, colonic pull-through for Hirschsprung disease, and other complex procedures can be done faster by using minimally invasive methods. For these and other operations, speed follows from precision, not the reverse.

Information Gain

MIS offers surgeons new options for resolving clinical uncertainty because

the cost to the patient is diminished, the power of exploration is greater than radiographic studies or other tests, or both.⁶⁴ For example, in malrotation, an upper gastrointestinal tract study may be nondiagnostic, but the stakes of missing malrotation are large, as volvulus, although rare, may be catastrophic. Laparoscopic exploration reliably diagnoses malrotation, and can provide information that contrast studies cannot. Meanwhile, the laparoscopic Ladd procedure is at least as effective in preventing volvulus as the open Ladd operation.⁵¹

The laparoscopic approach to malrotation illustrates how the surgeon can exploit information without delay by effecting definitive repair at the same time that the information is gained. In inguinal hernia, game theory (unpublished results) suggests that routine open exploration of an asymptomatic contralateral hernia holds a poor expected value because the low general probability of finding a second hernia and preventing a second operation does not offset the high cost to the patient of blind exploration. However, laparoscopic exploration quickly confirms or excludes contralateral hernia with high sensitivity and specificity, while also leaving the spermatic cord untouched, whereas laparoscopic inguinal hernia repair appears to provide similar or superior results with new techniques.^{65–67} Similarly, in appendicitis, often the diagnosis is incorrect, even in the age of near-ubiquitous computed tomography scanning.⁶⁸ The laparoscopic approach affords the surgeon the chance to both identify and remedy the real problem (eg, ovarian cyst or a Meckel diverticulitis) at relatively low cost to the patient. Surgeons performing appendectomy through a very small open incision can miss other surgical disease. Similar information gain at low patient cost can be found in pediatric trauma,⁶⁹ cancer,^{70–72}

and neonatal jaundice,^{73,74} but in these cases, repair or resection may require an open approach.

CHALLENGES TO MIS IN SMALL PATIENTS

Technological Limits

The challenges to MIS in small patients can be as great as the advantages. First, of course, not every pediatric surgical case should be forced into an MIS approach. For example, although laparoscopy and thoracoscopy can resolve uncertainties in trauma, an MIS approach is not right for, say, a patient with high-velocity penetrating trauma and hemodynamic instability. Not only does the surgeon have diminished degrees of freedom of motion, but palpation is restricted. These limits seem more constraining in small patients, where even small instruments seem large compared with the patient (Fig 4). Meanwhile, manufacturers have been slow to produce products especially adapted to infants and children. For example, no 3-mm, 20-cm ultrasonic shears are available, leaving surgeons the choice of using a blunt instrument longer than the patient, or altering technique to incorporate different technology.

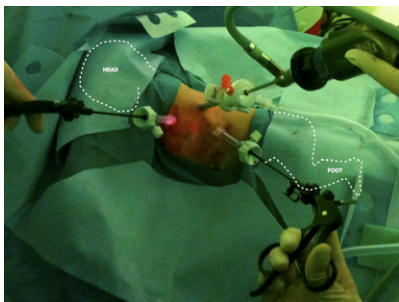


FIGURE 4

Small instruments and a pediatric-size 4 mm × 20 cm telescope still appear large compared with this infant patient, whose left chest is visible through the drapes. Head and feet are outlined (white dotted line). In this 3.5-kg infant, the entire hemithorax volume is only ~150 mL, and does not expand. Collapse of the lung may allow, perhaps, recruitment of about one-third this space, confining the work to a volume on the order of a golf ball (~38.8 cm³).

Skill and Precision

Clumsy minimally invasive technique is not “minimally invasive.” For example, a patient has not benefited from MIS when left under general anesthesia for 10 hours while the surgeon struggles with a new approach to a case that normally takes 90 minutes.^{43,62} Meanwhile, ergonomic problems create discomfort and fatigue that degrade fine motor movement, leading to imprecision and “accidental” moves. Minimally invasive methods require a different set of surgical skills, and the difficulties that minimally invasive methods present are magnified in small patients. One center’s experience with laparoscopic repair of duodenal atresia illustrates the point: van der Zee⁵³ reports that in the early part of the 2000s, their center abandoned laparoscopic duodenal atresia repair in infants after unacceptably high rates of leaks and other complications. Later, they were able to report entirely different results, but only after “considerable adjustments in technique and extensive improvement in experience.” Similar concerns have been raised for Kasai procedures⁷⁵ and congenital diaphragmatic hernia repairs.⁵⁷

Scaling

Isometric scaling determines the mechanical constraints that vary geometrically with size, such as the familiar increase in body surface area to volume ratio with decreasing body size. A pediatric patient one-half as tall as an adult presents the surgeon with only one-eighth the working volume in the chest or abdomen. This tiny volume demands much finer movements, and limits tolerance for slips. For example, friction in the trocars can bind the instruments slightly, producing a lurch when the static coefficient of friction is translated to the dynamic coefficient. If the working volume is small, this kind of lurch can seriously damage

liver, spleen, or other organs (where slips are made worse by the relatively weaker tissue strength of these organs in infants).

Similarly, very small working volumes raise the risk of inadvertent damage from surgical energy tools. The equation

$$T = T_0 + \left(\frac{J^2}{\sigma \rho C} \right) t, \text{ where}$$

T = final temperature

T_0 = starting temperature

J = current density (A/m²)

σ = electrical conductivity (Siemens/m)

ρ = tissue density (kg/m³)

C = specific heat of tissue (joules/kg/°C)

t = time duration of application of energy,

governs the way that electrical energy from electrosurgical instruments translates into cauterization or cutting of tissue.⁷⁶ The equation reveals how energy can easily, and unintentionally, spread to adjacent structures in small volumes. For example, surgeons who take large “bites” of tissue with monopolar dissection tools will be forced to use longer activation times (t) to overcome the tissue density (ρ) and conductivity (σ). But this long activation time will also increase tissue temperature (T) in adjacent tissue, creating unintended damage (irreversible tissue damage may appear just above 50°C). Ultrasonic energy devices share this risk, but the damage may be harder to see, compounding the risk.⁷⁷ Experienced pediatric MIS experts specifically modify their technique to avoid these pitfalls, but the unexpected challenges are not limited to these simple geometric constraints.

Physiology also varies nonlinearly by body mass,⁷⁸ and these types of nonlinear physiologic differences are magnified

in MIS in small patients. Chief among these differences is the scaling of metabolic energy with body mass,⁷⁹ a relationship that determines several physiologic risks of MIS. For example, this allometric scaling determines vulnerability to hypothermia and hypercarbia.

Hypothermia

It may seem that MIS protects patients from hypothermia because there is no large incision to allow heat to escape; however, small patients can and do become cold during laparoscopy.^{80–84} Trocars and other instruments leak CO₂, and some leaks may be relatively large. To compensate, the surgeon must increase the CO₂ flow to maintain adequate pneumoperitoneum for visualization. The CO₂ is relatively cool, but more importantly, it is dry. A straightforward thermodynamic calculation shows that this high-flowing gas cools patients, not from the heat energy carried away by the gas, but from evaporative losses.⁸⁵

For example, in a 4-kg infant, dry gas flowing at 6 to 8 L/min can create evaporative cooling that consumes a large fraction of the infant's metabolic rate. This evaporative cooling occurs despite large per-kilogram metabolic power exhibited by human infants. That same 4-kg infant has a metabolic rate of ~115 kcal/kg/d, or about 5.6 W/kg. In contrast, a 70-kg adult has a metabolic power ~35 kcal/kg/d (1.7 W/kg). On a unit-mass scale, infants burn far more fuel than adults; however, the total metabolic power of the infant is just over 22 W, compared with 119 W for the adult. In the infant, the evaporative loss is just 14 mL of water in an hour (the amount lost if CO₂ becomes 50% saturated while blowing continuously for 5 to 8 L/min). This produces 9 W of heat loss, or nearly 40% of the infant's metabolic power (however, this is <8% of the adult's metabolic power).

Because the child under anesthesia has no mechanism for raising metabolic rate to match this loss, cooling must follow.

Fortunately, just as physics reveals the cause, it also provides a solution: humidify the gas, and evaporative losses drop to near nothing.⁸⁶ Meanwhile, warming the CO₂ theoretically should have no effect (or make the problem worse), and experimentally does not work.⁸⁷ Alternatively, evaporation is attenuated by reducing the amount of gas that leaks from instruments. For this and other reasons, experienced pediatric MIS surgeons often fuss over the design and maintenance of pediatric MIS equipment.

Hypercarbia

Hypercarbia produces acidosis, decreased cerebral perfusion, and other hazards.⁸⁸ In MIS, CO₂ peritoneum and pneumothorax decrease CO₂ elimination 2 ways: by increasing the CO₂ load by absorption, and by reducing minute ventilation by restricting tidal volume.⁸⁹ Both of these effects appear to be magnified in small patients; ~10% to 20% of exhaled CO₂ in children during laparoscopy is absorbed by the peritoneum.⁹⁰ The anesthesiologist must compensate for this, but is limited by the added pressure in the abdomen. An anesthesiologist who fears "barotrauma" and lets the tidal volume slip during laparoscopy will see the infant's CO₂ rise. Because tidal volume scales isometrically (about 7 to 8 mL/kg/ breath), whereas CO₂ production scales allometrically, respiratory rate (and thus minute ventilation) must be disproportionately higher in infants.⁹¹ Like metabolic power, respiratory rate varies as an inverse power-law (Fig 5). Infants require not only higher baseline respiratory rates, but disproportionately larger increases in respiratory rate than adults to compensate for insufflation.

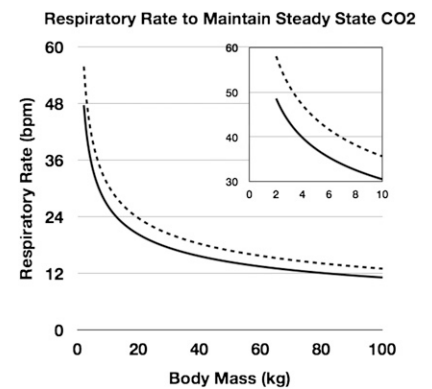


FIGURE 5

A simple mathematical model shows how respiratory rate follows an inverse power law determined by body mass (solid line). CO₂ insufflation shifts the curve upward (dotted line). The inset illustrates how this shift is more pronounced for children <10 kg. Not only do infants require a higher baseline respiratory rate, but they require disproportionately larger increases in respiratory rate than adults to compensate for insufflation.

FUTURE DIRECTIONS AND TECHNIQUES

Single-Incision Laparoscopic Surgery

Despite multiple studies showing that laparoscopic surgery produces less pain, shorter hospital stays, and improved cosmesis, surgeons wanted to try to do even better. This impulse led to single-incision laparoscopic surgery. This technique involves placing all of the instruments through 1 tiny incision hidden within the umbilical cicatrix. In 2009, Ponsky et al^{92–94} reported the first experience of single-port surgery in children, describing 72 single-port procedures performed at a single institution over 1 year, showing the method to be a safe alternative to traditional laparoscopy and open surgery. Pediatric surgeons around the world now perform single-port appendectomies, cholecystectomies, and other operations.^{92,94–98} Still, this approach creates mechanical disadvantages that probably limit its use. First, because all of the instruments traverse the same incision, the mechanical advantage is poor. Instruments tend to clash, and the classic

“triangulation” of the instruments is lost. Newer, articulated instruments may overcome some limitations, but still require the surgeon to work “backward,” and with reduced degrees of freedom. These constraints increase operating time, and restrict the complexity of case type that can be attempted to simple appendectomy, uncomplicated cholecystectomy, and a few others.⁹⁴ Furthermore, the umbilical incision must be relatively large to fit all of the instruments through the same opening. Although data are scant, theoretically this larger incision may lead to increased postoperative pain and increased wound hernia rates (see section Incision Advantages, earlier in this article). Single-port surgery in its current form is usually more difficult than the traditional laparoscopic approach,^{99–101} with unpublished reports of increased intraoperative complications and extended operating time. Because the only demonstrated benefit of single-port surgery is cosmetic,¹⁰² more work and, probably, new technology will be needed to fulfill the method’s potential (see the section Robotic Surgery, later in this article).

“Needlescopic” or “Minilaparoscopy”

Dissatisfaction with single-port methods has led others to explore methods in which working ports use trocars with very small outer diameters, or even in which the 2- or 3-mm instruments are inserted directly through the abdominal wall. These incisions are so small that they can be sealed with dermal glue and no sutures. Free from many constraints of single-port methods, minilaparoscopy produces a similar cosmetically pleasing outcome but is easier for the surgeon. Total wound tensions (and associated complications) are minimized. Minilaparoscopy uses instruments and methods developed by pediatric surgeons; advanced MIS technique has begun to flow back from

the pediatric to the adult surgical world.^{103–108}

Robotic Surgery

Robotic surgery uses the same basic techniques of laparoscopic surgery; however, instead of moving the instruments directly, the surgeon guides robotic arms designed to accurately mirror the motion and dexterity of human hands. They do not operate independently. In this way, current surgical “robots” are not really robots at all, but advanced telemanipulators. Nevertheless, the term “surgical robot” has stuck.

The surgeon controls the robot from a remote console consisting of a 3-dimensional viewer and fine finger controls. The surgical robot is a tool for enhancing precision: very advanced manipulations (such as extensive suturing) are often more feasible with the robot than with standard laparoscopy. However, robotic surgery has not gained as much interest as some anticipated. The robot has a large dollar cost, necessitates use of larger trocars, and requires extra training for the staff.¹¹ In pediatric surgery, as with the early experiences in laparoscopy, it has been easier to show feasibility than advantage. Albassam et al¹⁰⁹ compared standard laparoscopy in children with robotic surgery and showed no significant differences in postoperative complication rates, postoperative analgesic requirements, or lengths of hospital stay. They concluded that robotic surgery is feasible and safe, but, given the significant cost, should be limited to specific cases. Still, any technology that improves precision and mechanical advantage improves surgical technique. With more advanced technology and reduced costs, robotic surgery may find a more prominent role in pediatric surgery. In particular, combining new robotic equipment with single-incision approaches may overcome the limitations of single-incision methods by

taking full advantage of the reach and precision of telemanipulators.^{110–113}

Natural Orifice Transluminal Endoscopic Surgery

Although single-port surgery promises 1 scar, there is interest in performing surgery with no abdominal scar. Natural orifice transluminal endoscopic surgery (NOTES), allows surgeons to perform surgery without any incisions in the abdominal wall. With multi-channel endoscopes, the peritoneal cavity is accessed through either the stomach or vagina.¹¹⁴ Then the operation can be performed by passing specially designed instruments through the working channels of the endoscope. This technique has been described for appendectomies and cholecystectomies. The greatest challenge to NOTES is closure of the hole created in either the stomach or vagina. Although NOTES has not been widely used by pediatric surgeons, a recent report by Velhote and Velhote¹¹⁵ describe a NOTES technique with transanal endorectal pull-through surgery for a patient with Hirschsprung disease, allowing mobilization of the sigmoid colon without abdominal incisions. Others are investigating hybrid techniques combining NOTES with minilaparoscopy, using NOTES for treating esophageal atresia,¹¹⁶ and other uses. Despite these explorations, NOTES has barely touched pediatric surgery and its contributions are not yet clear.

CONCLUSIONS

The technical and technological aspects of pediatric MIS show that MIS is more than technique and technology; it is a choice. The hospital must choose to install the right equipment, bear higher instrument attrition costs, specially train the staff, and tolerate new learning curves. The surgeon must choose to add unfamiliar and uncomfortable methods to his repertoire, often after

his formal training has ended. He must also choose the patients for whom MIS can really reduce risks: there is a demonstrable gap between “can” and “should.” Still, promised

benefits are driving pediatric surgeon adoption as well as parental demand, and spurring innovations to overcome the challenges. Properly applied, MIS may offer better information, similar

(or superior) mechanical results, more surgical options, shorter hospital stays, and lower costs, both in terms of dollar amount and risks to the pediatric patient.

REFERENCES

- Holcomb GW, Georgeson K, Rothenberg S. *Atlas of Pediatric Laparoscopy and Thoracoscopy*. Philadelphia, PA: Saunders/Elsevier; 2008. p. xvi, 315
- Rothenberg SS, Chang JH, Bealer JF. Experience with minimally invasive surgery in infants. *Am J Surg*. 1998;176(6):654–658
- Rothenberg SS, Partrick DA, Bealer JF, Chang JH. Evaluation of minimally invasive approaches to achalasia in children. *J Pediatr Surg*. 2001;36(5):808–810
- Rothenberg SS. Thoracoscopic repair of esophageal atresia and tracheo-esophageal fistula. *Semin Pediatr Surg*. 2005;14(1):2–7
- Kushch NL, Timchenko AD. Laparoscopy in children [in Russian]. *Vestn Khir Im I I Grek*. 1969;102(5):92–94
- Cognat M, Rosenberg D, David L, Paathanassiou Z. Laparoscopy in infants and adolescents. *Obstet Gynecol*. 1973;42(4):515–521
- Cognat M, Papathanassiou Z, Gomel V. Laparoscopy in infants and adolescents. *J Reprod Med*. 1974;13(1):11–12
- Rodgers BM, Vries JK, Talbert JL. Laparoscopy in the diagnosis and treatment of malfunctioning ventriculo-peritoneal shunts in children. *J Pediatr Surg*. 1978;13(3):247–253
- Leape LL, Ramenofsky ML. Laparoscopy in children. *Pediatrics*. 1980;66(2):215–220
- Jones VS, Cohen RC. Two decades of minimally invasive pediatric surgery-taking stock. *J Pediatr Surg*. 2008;43(9):1653–1659
- Woo R, Le D, Krummel TM, Albanese C. Robot-assisted pediatric surgery. *Am J Surg*. 2004;188(suppl 4A):27S–37S
- Passerotti C, Peters CA. Robotic-assisted laparoscopy applied to reconstructive surgeries in children. *World J Urol*. 2006;24(2):193–197
- Sweeney DD, Smaldone MC, Docimo SG. Minimally invasive surgery for urologic disease in children. *Nat Clin Pract Urol*. 2007;4(1):26–38
- Mühe E. Long-term follow-up after laparoscopic cholecystectomy. *Endoscopy*. 1992;24(9):754–758
- Rangel SJ, Henry MC, Brindle M, Moss RL. Small evidence for small incisions: pediatric laparoscopy and the need for more rigorous evaluation of novel surgical therapies. *J Pediatr Surg*. 2003;38(10):1429–1433
- Ponsky TA, Rothenberg SS. Minimally invasive surgery in infants less than 5 kg: experience of 649 cases. *Surg Endosc*. 2008;22(10):2214–2219
- Ure BM, Bax NM, van der Zee DC. Laparoscopy in infants and children: a prospective study on feasibility and the impact on routine surgery. *J Pediatr Surg*. 2000;35(8):1170–1173
- Holcomb GW III, Olsen DO, Sharp KW. Laparoscopic cholecystectomy in the pediatric patient. *J Pediatr Surg*. 1991;26(10):1186–1190
- Kuebler JF, Ure BM. Minimally invasive surgery in the neonate. *Semin Fetal Neonatal Med*. 2011;16(3):151–156
- Georgeson KE, Robertson DJ. Minimally invasive surgery in the neonate: review of current evidence. *Semin Perinatol*. 2004;28(3):212–220
- Goldberg M. Mathematical note on wound tension and healing of surgical wounds. *Dermatol Surg*. 1999;25(10):828
- Byard RW, Gehl A, Tsokos M. Skin tension and cleavage lines (Langer's lines) causing distortion of ante- and postmortem wound morphology. *Int J Legal Med*. 2005;119(4):226–230
- Chaudhuri V, Potts BR, Karasek MA. Mechanisms of microvascular wound repair I. Role of mitosis, oxygen tension, and I-kappa B. *In Vitro Cell Dev Biol Anim*. 2006;42(10):308–313
- Wang HQ, Zhao L. Impact of mechanical stress and tension-stress on angiogenesis in wound healing. *Chin J Traumatol*. 2006;9(2):118–124
- Morin G, Rand M, Burgess LP, Voussoughi J, Graeber GM. Wound healing: relationship of wound closing tension to tensile strength in rats. *Laryngoscope*. 1989;99(8 pt 1):783–788
- Burgess LP, Morin GV, Rand M, Vossoughi J, Hollinger JO. Wound healing. Relationship of wound closing tension to scar width in rats. *Arch Otolaryngol Head Neck Surg*. 1990;116(7):798–802
- Högström H, Haglund U, Zederfeldt B. Tension leads to increased neutrophil accumulation and decreased laparotomy wound strength. *Surgery*. 1990;107(2):215–219
- Sharma M, Adamsons RJ, Enquist IF. The effect of excess suture tension on musculofascial wound healing. *Curr Surg*. 1990;47(4):255–257
- Blinman T. Incisions do not simply sum. *Surg Endosc*. 2010;24(7):1746–1751
- Luks FI, Logan J, Breuer CK, Kurkchubasche AG, Wesselhoeft CW Jr, Tracy TF Jr. Cost-effectiveness of laparoscopy in children. *Arch Pediatr Adolesc Med*. 1999;153(9):965–968
- Stanfill AB, Pearl RH, Kalvakuri K, Wallace LJ, Vegunta RK. Laparoscopic Ladd's procedure: treatment of choice for midgut malrotation in infants and children. *J Laparoendosc Adv Surg Tech A*. 2010;20(4):369–372
- Zitsman JL. Current concepts in minimal access surgery for children. *Pediatrics*. 2003;111(6 pt 1):1239–1252
- Varela JE, Wilson SE, Nguyen NT. Laparoscopic surgery significantly reduces surgical-site infections compared with open surgery. *Surg Endosc*. 2010;24(2):270–276
- Bowater RJ, Stirling SA, Lilford RJ. Is antibiotic prophylaxis in surgery a generally effective intervention? Testing a generic hypothesis over a set of meta-analyses. *Ann Surg*. 2009;249(4):551–556
- Yagmurlu A, Barnhart DC, Vernon A, Georgeson KE, Harmon CM. Comparison of the incidence of complications in open and laparoscopic pyloromyotomy: a concurrent single institution series. *J Pediatr Surg*. 2004;39(3):292–296, discussion 292–296
- Korovessis P, Papanastasiou D, Dimas A, Karayannis A. Scoliosis by acquired rib fusion after thoracotomy in infancy. *Eur Spine J*. 1993;2(1):53–55
- Van Biezen FC, Bakx PA, De Villeneuve VH, Hop WC. Scoliosis in children after thoracotomy for aortic coarctation. *J Bone Joint Surg Am*. 1993;75(4):514–518
- Wong-Chung J, France J, Gillespie R. Scoliosis caused by rib fusion after thoracotomy for

- esophageal atresia. Report of a case and review of the literature. *Spine*. 1992;17(7):851–854
39. Gilsanz V, Boechat IM, Birnberg FA, King JD. Scoliosis after thoracotomy for esophageal atresia. *AJR Am J Roentgenol*. 1983;141(3):457–460
 40. Lawal TA, Gosemann JH, Kuebler JF, Glüer S, Ure BM. Thoracoscopy versus thoracotomy improves midterm musculoskeletal status and cosmesis in infants and children. *Ann Thorac Surg*. 2009;87(1):224–228
 41. Barmparas G, Branco BC, Schnüriger B, Lam L, Inaba K, Demetriades D. The incidence and risk factors of post-laparotomy adhesive small bowel obstruction. *J Gastrointest Surg*. 2010;14(10):1619–1628
 42. Bax NM, Ure BM, van der Zee DC, van Tuijl I. Laparoscopic duodenoduodenostomy for duodenal atresia. *Surg Endosc*. 2001;15(2):217
 43. Georgeson KE, Owings E. Advances in minimally invasive surgery in children. *Am J Surg*. 2000;180(5):362–364
 44. Fox D, Morrato E, Campagna EJ, et al. Outcomes of laparoscopic versus open fundoplication in children's hospitals: 2005–2008. *Pediatrics*. 2011;127(5):872–880
 45. Frezza EE, Wachtel MS, Ewing BT. Bariatric surgery costs and implications for hospital margins: comparing laparoscopic gastric bypass and laparoscopic gastric banding. *Surg Laparosc Endosc Percutan Tech*. 2007;17(4):239–244
 46. Khajanchee YS, Kenyon TA, Hansen PD, Swanström LL. Economic evaluation of laparoscopic and open inguinal herniorrhaphies: the effect of cost-containment measures and internal hospital policy decisions on costs and charges. *Hernia*. 2004;8(3):196–202
 47. Heslin MJ, Winzeler AH, Weingarten JO, Diethelm AG, Urist MM, Bland KI. Laparoscopic adrenalectomy and splenectomy are safe and reduce hospital stay and charges. *Am Surg*. 2003;69(5):377–381
 48. Apelgren K. Hospital charges for Nissen fundoplication and other laparoscopic procedures. *Surg Endosc*. 1996;10(3):359–360
 49. Apelgren KN. A contemporaneous comparison of hospital charges for laparoscopic and open Nissen fundoplication. *Surg Endosc*. 1995;9(2):156–157
 50. Jordan AM. Hospital charges for laparoscopic and open cholecystectomy. *JAMA*. 1991;266(24):3425–3426
 51. Arrow KJ. Uncertainty and the welfare economics of medical care. 1963. *J Health Polit Policy Law*. 2001;26(5):851–883
 52. Skelly CL, Jackson CC, Wu Y, Hill CB, Chwals WJ, Liu DC. Thoracoscopic thymectomy in children with myasthenia gravis. *Am Surg*. 2003;69(12):1087–1089
 53. van der Zee DC. Laparoscopic repair of duodenal atresia: revisited. *World J Surg*. 2011;35(8):1781–1784
 54. Aziz O, Athanasiou T, Tekkis PP, et al. Laparoscopic versus open appendectomy in children: a meta-analysis. *Ann Surg*. 2006;243(1):17–27
 55. Stylopoulos N, Rattner DW. The history of hiatal hernia surgery: from Bowditch to laparoscopy. *Ann Surg*. 2005;241(1):185–193
 56. Shah SR, Jegapragasan M, Fox MD, Prince JM, Segura BJ, Kane TD. A review of laparoscopic Nissen fundoplication in children weighing less than 5 kg. *J Pediatr Surg*. 2010;45(6):1165–1168
 57. Gander JW, Fisher JC, Gross ER, et al. Early recurrence of congenital diaphragmatic hernia is higher after thoracoscopic than open repair: a single institutional study. *J Pediatr Surg*. 2011;46(7):1303–1308
 58. Jackson TD, Wannares JJ, Lancaster RT, Rattner DW, Hutter MM. Does speed matter? The impact of operative time on outcome in laparoscopic surgery. *Surg Endosc*. 2011;25(7):2288–2295
 59. Ford WD, Crameri JA, Holland AJ. The learning curve for laparoscopic pyloromyotomy. *J Pediatr Surg*. 1997;32(4):552–554
 60. Fujimoto T, Lane GJ, Segawa O, Esaki S, Miyano T. Laparoscopic extramucosal pyloromyotomy versus open pyloromyotomy for infantile hypertrophic pyloric stenosis: which is better? *J Pediatr Surg*. 1999;34(2):370–372
 61. Oak SN, Parelkar SV, Akhtar T, et al. Minimal access surgery in children—5 years institutional experience. *J Minim Access Surg*. 2005;1(3):121–128
 62. Oomen MW, Hoekstra LT, Bakx R, Heij HA. Learning curves for pediatric laparoscopy: how many operations are enough? The Amsterdam experience with laparoscopic pyloromyotomy. *Surg Endosc*. 2010;24(8):1829–1833
 63. Jia WQ, Tian JH, Yang KH et al. Open versus laparoscopic pyloromyotomy for pyloric stenosis: a meta-analysis of randomized controlled trials. *Eur J Pediatr Surg*. 2011;21(2):77–81
 64. Esposito C, Centonze A, Settini A. The efficacy of laparoscopy in detecting and treating associated congenital malformations in children. *Surg Endosc*. 2002;16(8):1242
 65. Chang YT. Technical refinements in single-port laparoscopic surgery of inguinal hernia in infants and children. *Diagn Ther Endosc*. 2010;2010:392847
 66. Chan KW, Lee KH, Tam YH, Sihoe JD, Cheung ST, Mou JW. Laparoscopic inguinal hernia repair by the hook method in emergency setting in children presenting with incarcerated inguinal hernia. *J Pediatr Surg*. 2011;46(10):1970–1973
 67. Tam YH, Lee KH, Sihoe JD, et al. Laparoscopic hernia repair in children by the hook method: a single-center series of 433 consecutive patients. *J Pediatr Surg*. 2009;44(8):1502–1505
 68. Partrick DA, Janik JE, Janik JS, Bensard DD, Karrer FM. Increased CT scan utilization does not improve the diagnostic accuracy of appendicitis in children. *J Pediatr Surg*. 2003;38(5):659–662
 69. Marwan A, Harmon CM, Georgeson KE, Smith GF, Muensterer OJ. Use of laparoscopy in the management of pediatric abdominal trauma. *J Trauma*. 2010;69(4):761–764
 70. Holcomb GW III, Tomita SS, Haase GM, et al. Minimally invasive surgery in children with cancer. *Cancer*. 1995;76(1):121–128
 71. Romano P, Avolio L, Martucciello G, Steyaert H, Valla JS. Adrenal masses in children: the role of minimally invasive surgery. *Surg Laparosc Endosc Percutan Tech*. 2007;17(6):504–507
 72. Gow KW, Saad DF, Koontz C, Wulkan ML. Minimally invasive thoracoscopic ultrasound for localization of pulmonary nodules in children. *J Pediatr Surg*. 2008;43(12):2315–2322
 73. Tang ST, Li SW, Ying Y, Mao YZ, Yong W, Tong QS. The evaluation of laparoscopy-assisted cholangiography in the diagnosis of prolonged jaundice in infants. *J Laparosc Adv Surg Tech A*. 2009;19(6):827–830
 74. Okazaki T, Miyano G, Yamataka A, et al. Diagnostic laparoscopy-assisted cholangiography in infants with prolonged jaundice. *Pediatr Surg Int*. 2006;22(2):140–143
 75. Ure BM, Kuebler JF, Schukfeh N, Engelmann C, Dingemann J, Petersen C. Survival with the native liver after laparoscopic versus conventional kasai portoenterostomy in infants with biliary atresia: a prospective trial. *Ann Surg*. 2011;253(4):826–830
 76. Van Way CW, Hinrichs CS. Electrosurgery 201: basic electrical principles. *Curr Surg*. 2000;57(3):261–264
 77. Koch C, Friedrich T, Metternich F, Tannapfel A, Reimann HP, Eichfeld U. Determination of temperature elevation in tissue during the application of the harmonic scalpel. *Ultrasound Med Biol*. 2003;29(2):301–309

78. Kleiber M. Body size and metabolic rate. *Physiol Rev.* 1947;27(4):511–541
79. Kolokotronis T, Van Savage J, Deeds EJ, Fontana W. Curvature in metabolic scaling. *Nature.* 2010;464(7289):753–756
80. Huntington TR, LeMaster CB. Laparoscopic hypothermia: heat loss from insufflation gas flow. *Surg Laparosc Endosc.* 1997;7(2):153–155
81. Bessell JR, Karatassas A, Patterson JR, Jamieson GG, Maddern GJ. Hypothermia induced by laparoscopic insufflation. A randomized study in a pig model. *Surg Endosc.* 1995;9(7):791–796
82. Seitzinger MR, Dudgeon LS. Decreasing the degree of hypothermia during prolonged laparoscopic procedures. *J Reprod Med.* 1993;38(7):511–513
83. Ott DE. Laparoscopic hypothermia. *J Laparoendosc Surg.* 1991;1(3):127–131
84. Ott DE. Correction of laparoscopic insufflation hypothermia. *J Laparoendosc Surg.* 1991;1(4):183–186
85. Gray RI, Ott DE, Henderson AC, Cochran SA, Roth EA. Severe local hypothermia from laparoscopic gas evaporative jet cooling: a mechanism to explain clinical observations. *JSLs.* 1999;3(3):171–177
86. Bessell JR, Ludbrook G, Millard SH, Baxter PS, Ubhi SS, Maddern GJ. Humidified gas prevents hypothermia induced by laparoscopic insufflation: a randomized controlled study in a pig model. *Surg Endosc.* 1999;13(2):101–105
87. Jacobs VR, Morrison JE Jr, Mettler L, Mundhenke C, Jonat W. Measurement of CO₂ hypothermia during laparoscopy and pelviscopy: how cold it gets and how to prevent it. *J Am Assoc Gynecol Laparosc.* 1999;6(3):289–295
88. Pollock JM, Deibler AR, Whitlow CT, et al. Hypercapnia-induced cerebral hyperperfusion: an underrecognized clinical entity. *AJNR Am J Neuroradiol.* 2009;30(2):378–385
89. Sanders JC, Gerstein N. Arterial to endtidal carbon dioxide gradient during pediatric laparoscopic fundoplication. *Paediatr Anaesth.* 2008;18(11):1096–1101
90. Pacilli M, Pierro A, Kingsley C, Curry JI, Herod J, Eaton S. Absorption of carbon dioxide during laparoscopy in children measured using a novel mass spectrometric technique. *Br J Anaesth.* 2006;97(2):215–219
91. Pennant JH. Anesthesia for laparoscopy in the pediatric patient. *Anesthesiol Clin North America.* 2001;19(1):69–88
92. Ponsky TA. Single port laparoscopic cholecystectomy in adults and children: tools and techniques. *J Am Coll Surg.* 2009;209(5):e1–e6
93. Ponsky TA, Diluciano J, Chwals W, Parry R, Boulanger S. Early experience with single-port laparoscopic surgery in children. *J Laparoendosc Adv Surg Tech A.* 2009;19(4):551–553
94. Ponsky TA, Krpata DM. Single-port laparoscopy: considerations in children. *J Minim Access Surg.* 2011;7(1):96–98
95. Zani A, Ade-Ajayi N. Flexible-tip laparoscopic surgery: a bridge to single port appendectomy in children. *Eur J Pediatr Surg.* 2011;21(5):322–324
96. de Armas IA, Garcia I, Pimpalwar A. Laparoscopic single port surgery in children using Triport: our early experience. *Pediatr Surg Int.* 2011;27(9):985–989
97. Agrawal S, Slovick A, Soon Y. Single-port laparoscopy for the drainage of abdominal infected fluid collections in children, with the TriPort system: initial experience of 2 cases. *Surg Innov.* 2010;17(3):261–263
98. Rothenberg SS, Shipman K, Yoder S. Experience with modified single-port laparoscopic procedures in children. *J Laparoendosc Adv Surg Tech A.* 2009;19(5):695–698
99. Han HJ, Choi SB, Park MS, et al. Learning curve of single port laparoscopic cholecystectomy determined using the non-linear ordinary least squares method based on a non-linear regression model: An analysis of 150 consecutive patients. *J Hepatobiliary Pancreat Sci.* 2011;18(4):510–515
100. Escobar PF, Starks DC, Fader AN, Barber M, Rojas-Espalliat L. Single-port risk-reducing salpingo-oophorectomy with and without hysterectomy: surgical outcomes and learning curve analysis. *Gynecol Oncol.* 2010;119(1):43–47
101. Kravetz AJ, Iddings D, Basson MD, Kia MA. The learning curve with single-port cholecystectomy. *JSLs.* 2009;13(3):332–336
102. Vettoretto N, Mandalà V. Single port laparoscopic appendectomy: are we pursuing real advantages? *World J Emerg Surg.* 2011;6:25
103. Franklin ME Jr, Jaramillo EJ, Glass JL, Treviño JM, Berghoff KR. Needlescopic cholecystectomy: lessons learned in 10 years of experience. *JSLs.* 2006;10(1):43–46
104. Shalaby R, Desoky A. Needlescopic inguinal hernia repair in children. *Pediatr Surg Int.* 2002;18(2-3):153–156
105. Shalaby R, Shams AM, Mohamed S, el-Leathy M, Ibrahim M, Alsaed G. Two-trocar needlescopic approach to incarcerated inguinal hernia in children. *J Pediatr Surg.* 2007;42(7):1259–1262
106. Shalaby RY, Fawy M, Soliman SM, Dorgham A. A new simplified technique for needlescopic inguinal herniorrhaphy in children. *J Pediatr Surg.* 2006;41(4):863–867
107. Tan HL. Laparoscopic Anderson-Hynes dismembered pyeloplasty in children using needlescopic instrumentation. *Urol Clin North Am.* 2001;28(1):43–51, viii
108. Lee KW, Poon CM, Leung KF, Lee DW, Ko CW. Two-port needlescopic cholecystectomy: prospective study of 100 cases. *Hong Kong Med J Acad Med.* 2005;11(1):30–35
109. Albassam AA, Mallick MS, Gado A, Shoukry M. Nissen fundoplication, robotic-assisted versus laparoscopic procedure: a comparative study in children. *Eur J Pediatr Surg.* 2009;19(5):316–319
110. Wren SM, Curet MJ. Single-port robotic cholecystectomy: results from a first human use clinical study of the new da Vinci single-site surgical platform. *Arch Surg.* 2011;146(10):1122–1127
111. Kroh M, El-Hayek K, Rosenblatt S, et al. First human surgery with a novel single-port robotic system: cholecystectomy using the da Vinci Single-Site platform. *Surg Endosc.* 2011;25(11):3566–3573
112. Escobar PF, Kebria M, Falcone T. Evaluation of a novel single-port robotic platform in the cadaver model for the performance of various procedures in gynecologic oncology. *Gynecol Oncol.* 2011;120(3):380–384
113. Kaouk JH, Goel RK, Haber GP, Crouzet S, Stein RJ. Robotic single-port transumbilical surgery in humans: initial report. *BJU Int.* 2009;103(3):366–369
114. Clayman RV, Box GN, Abraham JB, et al. Rapid communication: transvaginal single-port NOTES nephrectomy: initial laboratory experience. *J Endourol.* 2007;21(6):640–644
115. Velhote MC, Velhote CE. A NOTES modification of the transanal pull-through. *J Laparoendosc Adv Surg Tech A.* 2009;19(2):255–257
116. Ishimaru T, Iwanaka T, Kawashima H, et al. A pilot study of laparoscopic gastric pull-up by using the natural orifice transluminal endoscopic surgery technique: a novel procedure for treating long-gap esophageal atresia (type a). *J Laparoendosc Adv Surg Tech A.* 2011;21(9):851–857

Pediatric Minimally Invasive Surgery: Laparoscopy and Thoracoscopy in Infants and Children

Thane Blinman and Todd Ponsky

Pediatrics 2012;130;539

DOI: 10.1542/peds.2011-2812 originally published online August 6, 2012;

Updated Information & Services

including high resolution figures, can be found at:
<http://pediatrics.aappublications.org/content/130/3/539>

References

This article cites 102 articles, 5 of which you can access for free at:
<http://pediatrics.aappublications.org/content/130/3/539.full#ref-list-1>

Subspecialty Collections

This article, along with others on similar topics, appears in the following collection(s):
Surgery
http://classic.pediatrics.aappublications.org/cgi/collection/surgery_surgery

Permissions & Licensing

Information about reproducing this article in parts (figures, tables) or in its entirety can be found online at:
<https://shop.aap.org/licensing-permissions/>

Reprints

Information about ordering reprints can be found online:
<http://classic.pediatrics.aappublications.org/content/reprints>

Pediatrics is the official journal of the American Academy of Pediatrics. A monthly publication, it has been published continuously since . Pediatrics is owned, published, and trademarked by the American Academy of Pediatrics, 141 Northwest Point Boulevard, Elk Grove Village, Illinois, 60007. Copyright © 2012 by the American Academy of Pediatrics. All rights reserved. Print ISSN: .

American Academy of Pediatrics

DEDICATED TO THE HEALTH OF ALL CHILDREN™



PEDIATRICS®

OFFICIAL JOURNAL OF THE AMERICAN ACADEMY OF PEDIATRICS

Pediatric Minimally Invasive Surgery: Laparoscopy and Thoracoscopy in Infants and Children

Thane Blinman and Todd Ponsky

Pediatrics 2012;130;539

DOI: 10.1542/peds.2011-2812 originally published online August 6, 2012;

The online version of this article, along with updated information and services, is located on the World Wide Web at:

<http://pediatrics.aappublications.org/content/130/3/539>

Pediatrics is the official journal of the American Academy of Pediatrics. A monthly publication, it has been published continuously since . Pediatrics is owned, published, and trademarked by the American Academy of Pediatrics, 141 Northwest Point Boulevard, Elk Grove Village, Illinois, 60007. Copyright © 2012 by the American Academy of Pediatrics. All rights reserved. Print ISSN: .

American Academy of Pediatrics

DEDICATED TO THE HEALTH OF ALL CHILDREN™

