

Surgery Illustrated – Focus on Details

Laparoscopic transposition of lower pole crossing vessels ('vascular hitch') in pure extrinsic pelvi-ureteric junction (PUJ) obstruction in children

Akiko Sakoda, Abraham Cherian and Imran Mushtaq

Great Ormond Street Hospital for Children NHS Trust, London, UK

ILLUSTRATIONS by STEPHAN SPITZER, www.spitzer-illustration.com

INTRODUCTION

PUJ obstruction in the older child may have an extrinsic aetiology due to a lower pole crossing vessel. The association was first described by von Rokitsky [1] in 1842 [2]. The 'gold standard' in the management of most intrinsic and extrinsic PUJ obstructions has been a dismembered pyeloplasty as described by Anderson and Hynes [3] in 1949. This principle has stood the test of time with excellent long-term outcomes with both open and laparoscopic/robotic

techniques. An alternative approach to pure extrinsic PUJ obstruction was first described by Hellström *et al.* [4] in 1949 and involved displacing and anchoring the lower pole vessels in a more cranial position on the anterior pelvic wall using vascular adventitial sutures. Chapman [5] further modified this technique by securing a more superior position of the lower pole vessels within a wrap of the anterior pelvic wall without the need for vascular adventitial sutures. This technique has since been described in children as an alternative to

open dismembered pyeloplasty with the largest series reported by Pesce *et al.* [6] in 1999 with excellent outcomes. The senior author reported the use of laparoscopy in performing this procedure in 2008, highlighting the importance of careful patient selection and outcomes [7]. In the technique described below the left kidney is approached transperitoneally through a window in the mesocolon. A 5-mm, 30 ° laparoscope and two other 5-mm working ports are triangulated for dissection and performing the pelvic wrap.

Figure 1

a, At laparoscopy the presence of a lower pole vessel is confirmed in the absence of a narrow PUJ. This is better visualised by an anterior approach transperitoneally or retroperitoneoscopically.

b, The PUJ and the adjoining pelvis is adequately mobilised achieving easy displacement of vessels more cranially on the anterior pelvic wall.

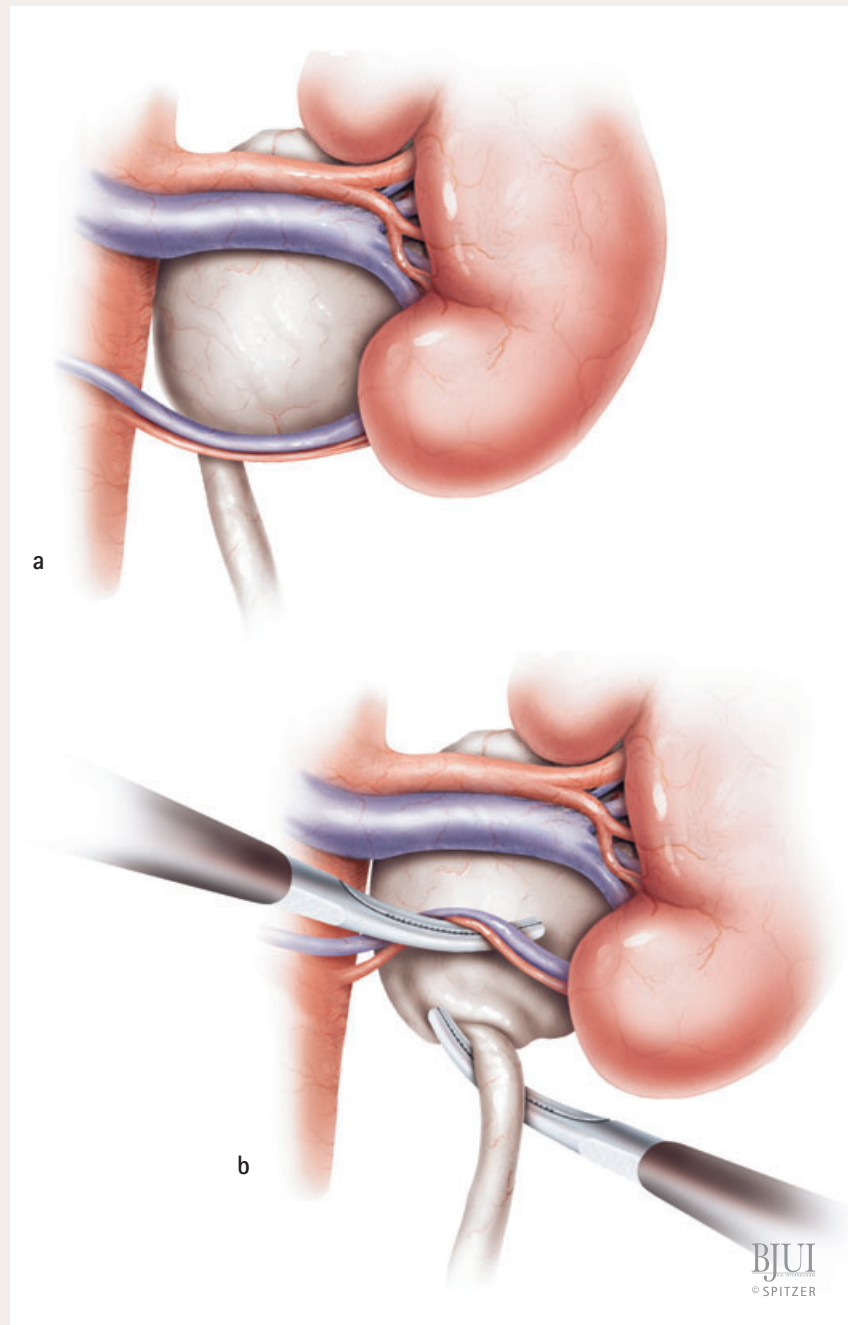


Figure 2a,b

The 'shoe-shine' manoeuvre of the mobilised anterior pelvis behind the lower pole vessels confirms adequate availability of the pelvis to perform a loose wrap around the vessels.

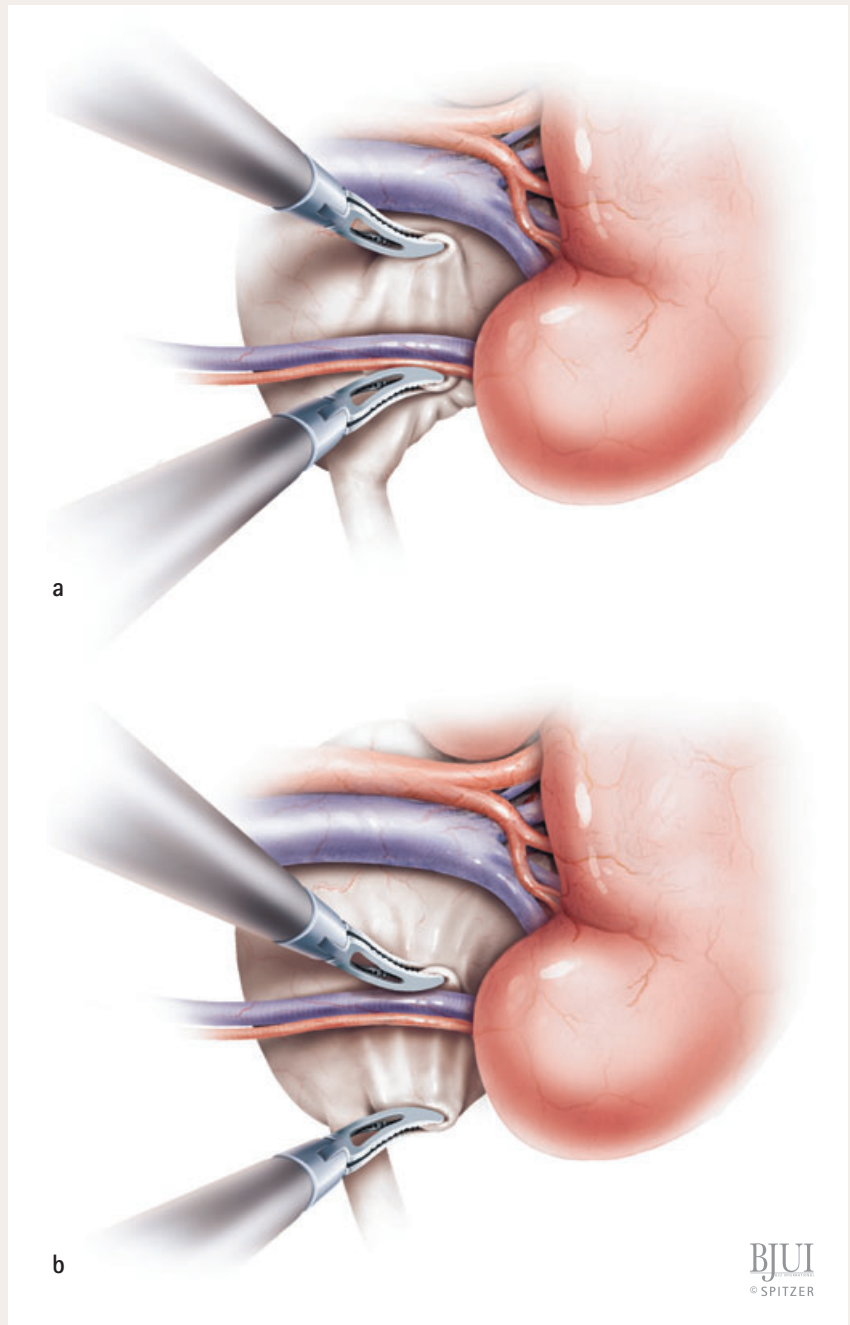
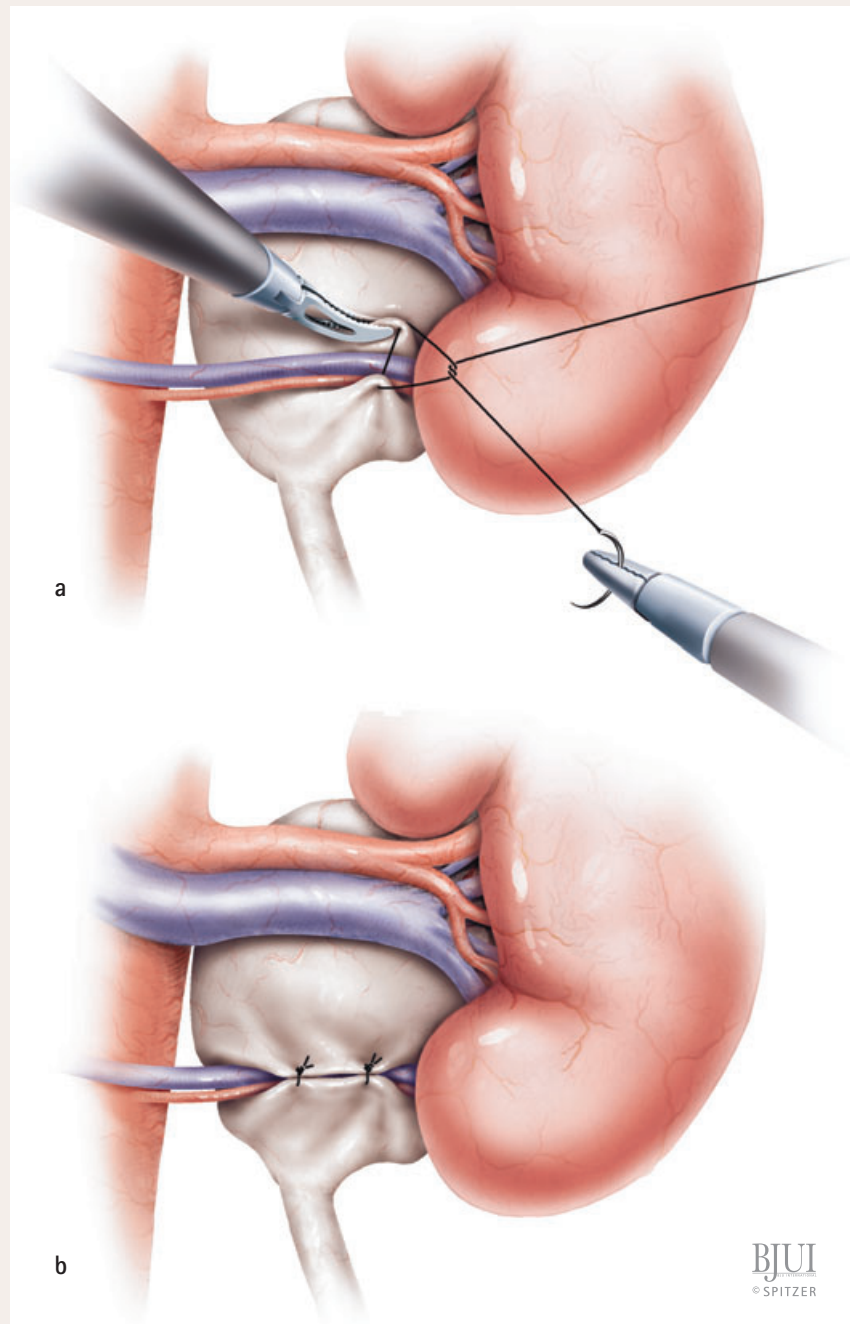


Figure 3

a, The cranially displaced lower pole vessels are positioned away from the PUJ by performing a loose wrap of the anterior pelvic wall around these vessels using 4/0 polydioxanone sutures.

b, Two or three interrupted sutures may be necessary to achieve an adequate tunnel within the anterior pelvic wall.



Older children presenting with a typical history of intermittent pain and associated intermittent hydronephrosis in the absence of any antenatal history should be considered to have lower pole crossing vessel. These children may therefore be candidates for the 'vascular hitch'. The main advantage of this procedure is that it avoids transection of the renal pelvis and minimises the possibility of a urinary leak from the anastomosis. In addition, the use of an internal stent is unnecessary and the procedure itself is less laborious than a laparoscopic dismembered pyeloplasty. With appropriate and careful patient selection, both preoperatively and during the procedure, this technique can achieve a successful outcome in up to 95% of patients [7].

REFERENCES

- 1 **Von Rokitsansky CF.** *Handbuch der Pathologischen Anatomie.* Vienna, Austria: Braumüller und Seidel, 1842
- 2 **Brosig W, Kollwitz AA.** Transposition of lower polar vessels: an operative approach to hydronephrosis. *J Urol* 1961; **85**: 453–8
- 3 **Anderson JC, Hynes W.** Retrocaval ureter; a case diagnosed pre-operatively and treated successfully by a plastic operation. *Br J Urol* 1949; **21**: 209–14
- 4 **Hellström J, Giertz G, Lindblom K.** *Pathogenesis and treatment of hydronephrosis.* Presented at VIII Congreso de la Sociedad Internacional de Urología, Paris, France, 1949
- 5 **Chapman TL.** *Urology in Outline.* Edinburgh, London: Churchill Livingstone, 1959: 82
- 6 **Pesce C, Campobasso P, Costa L, Battaglino F, Musi L.** Ureterovascular hydronephrosis in children: is pyeloplasty always necessary? *Eur Urol* 1999; **36**: 71–4
- 7 **Gundeti MS, Reynolds WS, Duffy PG, Mushtaq I.** Further experience with the vascular hitch (laparoscopic transposition of lower pole crossing vessels): an alternate treatment for pediatric ureterovascular ureteropelvic junction obstruction. *J Urol* 2008; **180** (Suppl.): 1832–6

Correspondence: Abraham Cherian, Department of Paediatric Urology, Great Ormond Street Hospital for Children NHS Trust, Great Ormond Street, London WC1N 3JH, UK.
e-mail: CheriA@gosh.nhs.uk