



Perforated peptic ulcer in the pediatric population: A case report and literature review



Sara Morrison^a, Peter Ngo^b, Bill Chiu^{a,*}

^a Department of Surgery, Tufts Medical Center, 800 Washington Street, Box #344, Boston, MA 02111, USA

^b Division of Gastroenterology, Hepatology and Nutrition, Boston Children's Hospital, Boston, MA, USA

ARTICLE INFO

Article history:

Received 19 July 2013

Received in revised form

13 August 2013

Accepted 13 August 2013

Key words:

Pediatric peptic ulcer disease

Pediatric duodenal perforation

ABSTRACT

We present a rare occurrence in modern day, western medicine, a case of a nine year old Asian female with a perforated duodenal ulcer. She presented with nausea, anorexia, and abdominal pain. On exam, she was febrile, tachycardic, with evidence of peritonitis. An upright abdominal film revealed a significant amount of pneumoperitoneum. The patient was taken to the operating room and underwent laparoscopic primary repair of a perforated ulcer in the first portion of the duodenum, buttressed with an omental patch. IgG for *Helicobacter pylori* was positive. We review the differential etiologies for perforation in children, along with the corresponding surgical and medical management of such disease processes.

© 2013 The Authors. Published by Elsevier Inc. Open access under [CC BY-NC-ND license](https://creativecommons.org/licenses/by-nc-nd/4.0/).

Potential etiologies of the acute surgical abdomen in infants and children are relatively few in number. A diagnosis that additionally accounts for the finding of significant pneumoperitoneum limits the consideration of possible etiologies even further. Care-takers of these patients are more oft to consider perforated appendicitis as a source of free air than the likelihood of a proximal perforation in an otherwise healthy child. The literature on perforated peptic ulcers in children in western countries is vastly outdated, with many case series written several decades ago [1–3]. There are more recent cases of duodenal perforation arising from developing countries with diverse endemic exposures, with reported etiologies including malaria, meningitis, gastro-enteritis, and lymphoma [4–7]. We present a rare case, particularly in western countries in the modern medical era, of a nine year old female who presented with peritonitis and pneumoperitoneum following the perforation of a duodenal ulcer.

1. Case report

The patient is a 9 year-old, previously healthy, Asian female, who was brought to the emergency room by her parents with

complaints of anorexia, nausea, and abdominal pain that began earlier that day. The child awoke in the morning with complaints initially of nausea, without emesis, though went to school as usual. In the afternoon, she noted a sudden onset of abdominal pain, particularly at her epigastrium, as well as her right lower abdomen and right shoulder. Her pain was exacerbated by movement, there were no alleviating factors. Her parents described a subjective fever, malaise, progressive discomfort and noted that she refused to eat, thus prompting the concern for medical evaluation. Bowel movements were reported to be regular; there was no exposure to sick contacts or pets, or a history of recent travel, trauma, or medical procedure. There was no history of chronic abdominal pain or non-steroidal anti-inflammatory drug use. Review of systems was otherwise negative. Her family was originally from China, though she was born in the United States. There was no known family history of inflammatory bowel disease, peptic ulcer disease or gastro-intestinal cancers in the family.

On exam, the patient appeared generally unwell, quiet, lying still on her stretcher. She was febrile to 102.9, and tachycardic to 135. Blood pressure and respiratory status on room air were normal. Chest and heart exams were unremarkable. Her right shoulder had a full range of motion, was not tender on exam, and demonstrated no evidence of trauma. The patient's abdomen revealed guarding, tenderness throughout, but particularly noted at the right lower quadrant and epigastrium. Peritoneal signs were elicited diffusely.

On review of her labs, the patient manifested a notable leukocytosis to 20 with an associated left shift. Other lab work including chemistries, coagulation parameters, and urinalysis were within

* Corresponding author. Tel.: +1 617 636 5025; fax: +1 617 636 8122.

E-mail address: bchiu@tuftsmedicalcenter.org (B. Chiu).

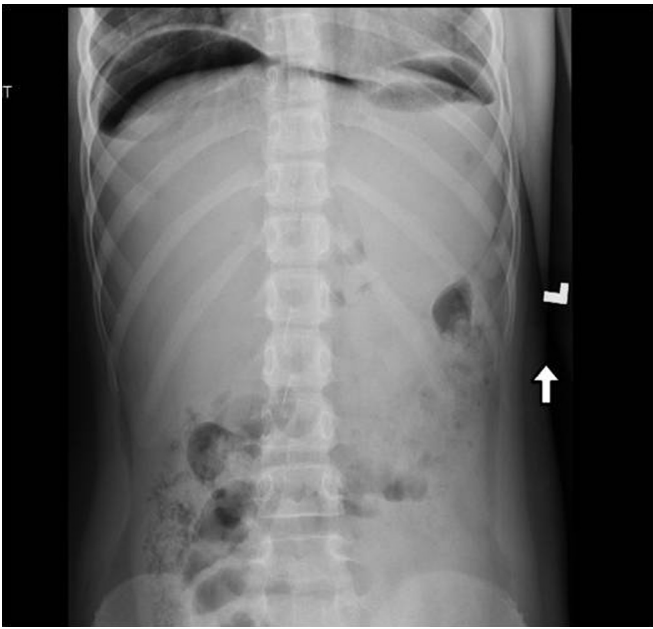


Fig. 1. Upright abdominal x-ray showing pneumoperitoneum.

normal limits. An ultrasound revealed free fluid in the pelvis, and an upright abdominal x-ray demonstrated pneumoperitoneum (Fig. 1). CT scan confirmed pneumoperitoneum but without extravasation of contrast. Thickened dilated loops of bowel were noted in the right lower quadrant, with free fluid. The appendix was not clearly identified, and no clear source of the perforation was identified.

The patient was then taken to the operating room for a diagnostic laparoscopy with the presumed diagnosis of perforated appendicitis. Upon entering the abdomen, diffuse fibrinous exudates were noted with purulent ascites. Attention was turned first to the right lower quadrant, where the appendix and adjacent bowel appeared inflamed. The appendix was removed, followed by aspiration and irrigation of the abdominal cavity. While irrigating, persistent exudate was noted around the gallbladder and liver bed, and with closer inspection, an efflux of bile was noted from the duodenum. Further separation of the fibrinous material revealed a 3 mm perforation at the first portion of the duodenum,

immediately distal to the pylorus (Fig. 2). The perforation was closed primarily with interrupted 3-0 silk sutures and buttressed with an omental patch (Figs. 3 and 4).

The patient's post-operative course was unremarkable. Immediately following the operation, Ertapenem was initiated based on the surgical findings of a perforated viscus with gross intra-abdominal contamination. This was given at an appropriate weight based dose, twice daily, intravenously for 7 days. A basal gastrin level was within normal limits, and serum *Helicobacter pylori* IgG returned positive. As such, proton pump inhibitor therapy was initiated. Although *H. pylori* fecal antigen assay was negative, this was presumed to be secondary to initiation of appropriate antibiotic therapy. The patient was discharged home on a regimen of proton pump inhibitor therapy to complete a six month course. Corresponding antibiotics were not continued in order to improve the sensitivity of the planned future esophagogastroduodenoscopy (EGD) and mucosal biopsies. Additionally, as the fecal antigen test was negative, thus there was no evidence of active *H. pylori* disease.

An EGD was performed six weeks following the initial presentation. The gastric mucosa was noted to have diffuse severe nodular antral gastritis consistent with *H. pylori* infection (Fig. 5). A urease breath test was negative, as were cultures from the mucosal biopsies and histologic stains for the organisms. These negative findings were attributed to a cleared infection following combined proton pump inhibitor and antibiotic therapy.

Six months later, the patient is pain-free and tolerating her diet. She remains without symptoms.

2. Discussion

Pneumoperitoneum and peritonitis following the perforation of a peptic ulcer is a rare cause of an acute abdomen in children and often results in a significant delay in diagnosis and subsequent operative management. This increases the likelihood of developing complications post-operatively [1,8]. Hua et al., describes a series of 52 patients with perforated peptic ulcer disease in the pediatric population. 90% of such patients were adolescents, and 80% of involved patients were male, again re-emphasizing the unusual occurrence of this disease process in our patient, a nine year old female [8]. Another series published in 1988, reviewed the management of 36 patients with peptic ulcer disease from ages 6 to 18. It was noted that in children under 10, all peptic ulcers were secondary in etiology; attributed to drug therapy or severe underlying

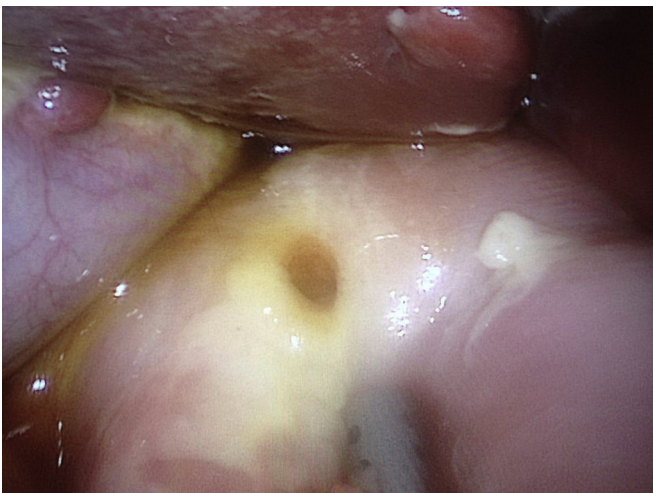


Fig. 2. Intraoperative photo, showing duodenal perforation.

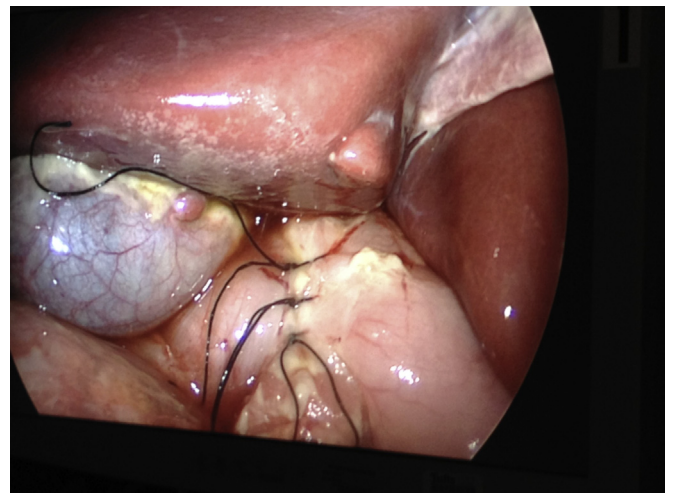


Fig. 3. Primary repair of the duodenal perforation.

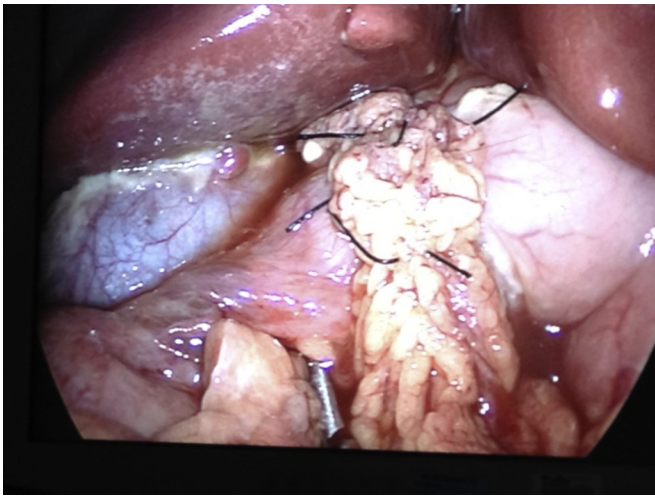


Fig. 4. Graham patch over the duodenal repair.

illness, or increased intracranial pressure. Patients over 10 with primary duodenal pathology had a high incidence of recurrent symptoms (67%) [3].

In the case we described, the underlying etiology was most likely related to *H. pylori* infection based on appearance of the stomach on endoscopy and positive serum IgG. Other described instances of perforation in Western countries implicate chronic steroid administration, NSAIDs, severe underlying illness, trauma, iatrogenic perforations from EGD, and air enemas in the radiologic reduction of intussusception [9–14]. Countries such as Nepal, West Africa, and India have reported cases secondary to meningitis, malaria, lymphoma, and gastro-enteritis [4–7,15]. A case series of two patients in Austria described the incidence of simultaneous acute appendicitis with a perforated ulcer [16]. In the Austrian case series, it is unclear if authors believe that the stress of the appendicitis in their patients may have been the triggering event for the perforation. In our case, the appendix and adjacent bowel were most likely inflamed secondary to the caustic bilious ascites

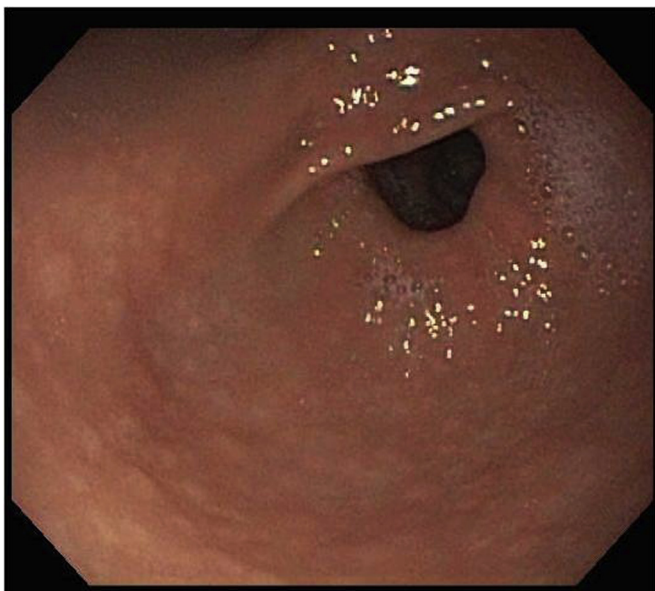


Fig. 5. Endoscopic evaluation of the gastric mucosa, showing diffuse severe nodular gastritis at the antrum.

resulting from the duodenal perforation, rather than serving as the primary pathology. This was, in fact, confirmed on the final pathology report, which diagnosed the inflammatory changes seen on the appendiceal viscera as acute fibrinopurulent serositis, rather than acute appendicitis.

Surgical management of children with perforated peptic ulcers has historically involved the use of open surgery. Laparoscopy has since been shown to be safe and effective in the treatment of children with complicated peptic ulcer disease [17,18]. In a series by Wong et al., 17 pediatric patients with perforated peptic ulcers were taken for diagnostic laparoscopy and underwent primary repair; 4 were converted to open secondary to technical difficulties and extent of the ulcer. Only two patients had recurrence of ulcer disease in the form of bleeding and were managed without surgery [18].

In the adult population, there is some debate on the role of including an antacid procedure for a stable patient at the time of initial surgery for a perforated peptic ulcer. The role of acid lowering procedures in children has not been studied extensively. Edwards et al. reported a series of 29 pediatric patients with complicated peptic ulcer disease, 5 were managed with an antacid procedure at the time of initial operation. However these were performed in instances of bleeding or gastric outlet obstruction, and may have been required to adequately treat the area of obstruction or bleeding. All patients in this series with perforation [16] were treated with simple repair with or without omental patch [11]. The consensus from review of the literature is consistent with our decision to treat the perforation with primary repair and omental buttress [17,18].

The prevalence of *H. pylori* infection has declined in the United States and Europe. Despite this, the prevalence remains high in Asia and the developing world. Transmission is thought to occur most frequently from person-to-person, and children are believed most commonly to acquire infection from their mothers. Most published studies demonstrate household crowding, sharing a bed with children, and sharing plates, spoons, or tasting food before feeding a child are related to infection in children [12,19]. *H. pylori* can be diagnosed via invasive and non-invasive means, which include endoscopy with biopsy, or a urease breath test, detection of antibodies in serum, urine, or saliva, or antigen in stool. To confirm a diagnosis of *H. pylori* infection, two tests are needed, one of which should be based on the results of biopsied tissue, either resulting in a culture, or histology or urease test. First line medical treatment includes a proton-pump inhibitor and two antibiotics for a period of 14 days, with the goal of eradicating 90% of the bacteria on the first course in order to prevent the development of resistant strains [19].

In our patient, the diagnosis of *H. pylori* seems likely, given her Asian heritage, positive serum IgG, and gastric appearance on endoscopy. However, the diagnosis cannot be formally confirmed, as biopsy culture and urease testing were negative.

3. Conclusion

This case represents a rare entity in pediatric emergency medicine. The incidence of perforated peptic ulcer in children has been decreasing in industrialized countries. Peptic ulcer disease secondary to *H. pylori* infection is particularly important to recognize due to the high reported incidence of recurrence. Laparoscopy is a safe and effective tool in the surgical management of complicated peptic ulcer disease in children. Perforation from peptic ulcer disease is adequately treated with primary closure, omental buttress, and medical management of the underlying etiology.

Conflict of interest statement

None of the authors have any financial or personal relationships with other people or organizations that could inappropriately influence this work. We have nothing to disclose.

References

- [1] Azarow K, Kim P, Shandling B, Ein SA. 45-year experience with surgical treatment of peptic ulcer disease in children. *J Pediatr Surg* 1996;31(6):750–3.
- [2] Deckelbaum RJ, Roy CC, Lussier-Lazaroff J, Morin CL. Peptic ulcer disease: a clinical study in 73 children. *Can Med Assoc J* 1974;111(3):225–8.
- [3] Drumm B, Rhoads JM, Stringer DA, Sherman PM, Ellis LE, Durie PR. Peptic ulcer disease in children: etiology, clinical findings, and clinical course. *Pediatrics* 1988;82(3 Pt 2):410–4.
- [4] Goldman N, Punguyire D, Osei-Kwakye K, Baiden F. Duodenal perforation in a 12-month old child with severe malaria. *Pan Afr Med J* 2012;12:1.
- [5] Tanzer F, Baskin E, Icli F, Toksoy H, Gokalp A. Perforated duodenal ulcer: an unusual complication of meningitis. *Turk J Pediatr* 1994;36(1):67–70.
- [6] Wilson JM, Darby CR. Perforated duodenal ulcer: an unusual complication of gastroenteritis. *Arch Dis Child* 1990;65(9):990–1.
- [7] Yadav RP, Agrawal CS, Gupta RK, Rajbansi S, Bajracharya A, Adhikary S. Perforated duodenal ulcer in a young child: an uncommon condition. *JNMA J Nepal Med Assoc* 2009;48(174):165–7.
- [8] Hua MC, Kong MS, Lai MW, Luo CC. Perforated peptic ulcer in children: a 20-year experience. *J Pediatr Gastroenterol Nutr* 2007;45(1):71–4. <http://dx.doi.org/10.1097/MPG.0b013e31804069cc>.
- [9] Bickler SW, Harrison MW, Campbell JR. Perforated peptic ulcer disease in children: association of corticosteroid therapy. *J Pediatr Surg* 1993;28(6):785–7.
- [10] Dohil R, Hassall E. Peptic ulcer disease in children. *Baillieres Best Pract Res Clin Gastroenterol* 2000;14(1):53–73.
- [11] Edwards MJ, Kollenberg SJ, Brandt ML, Wesson DE, Nuchtern JG, Minifee PK, et al. Surgery for peptic ulcer disease in children in the post-histamine2-blocker era. *J Pediatr Surg* 2005;40(5):850–4. <http://dx.doi.org/10.1016/j.jpedsurg.2005.01.056>.
- [12] Ertem D. Clinical practice: *Helicobacter pylori* infection in childhood. *Eur J Pediatr* 2012. <http://dx.doi.org/10.1007/s00431-012-1823-4>.
- [13] Schwartz S, Edden Y, Orkin B, Erlichman M. Perforated peptic ulcer in an adolescent girl. *Pediatr Emerg Care* 2012;28(7):709–11. <http://dx.doi.org/10.1097/PEC.0b013e31825d21c3>.
- [14] Sherman PM. Peptic ulcer disease in children. diagnosis, treatment, and the implication of *helicobacter pylori*. *Gastroenterol Clin North Am* 1994;23(4):707–25.
- [15] Nuhu A, Kassama Y. Experience with acute perforated duodenal ulcer in a West African population. *Niger J Med* 2008;17(4):403–6.
- [16] Toubanakis G. Perforated chronic duodenal ulcer in children with coexistence of acute appendicitis. *Aust Paediatr J* 1988;24(6):371–2.
- [17] Sanabria AE, Morales CH, Villegas MI. Laparoscopic repair for perforated peptic ulcer disease. *Cochrane Database Syst Rev* 2005;(4). <http://dx.doi.org/10.1002/14651858.CD004778.pub2>. CD004778.
- [18] Wong BP, Chao NS, Leung MW, Chung KW, Kwok WK, Liu KK. Complications of peptic ulcer disease in children and adolescents: minimally invasive treatments offer feasible surgical options. *J Pediatr Surg* 2006;41(12):2073–5. <http://dx.doi.org/10.1016/j.jpedsurg.2006.08.009>.
- [19] Ford AC, Axon AT. Epidemiology of *Helicobacter pylori* infection and public health implications. *Helicobacter* 2010;15(Suppl. 1):1–6.